

LYMPHOMA

Kenneth Alonso, MD, FACP

Lymph nodes

- Initial development from precursors in the central (also called primary) lymphoid organs
 - The bone marrow for B cells
 - The thymus for T cells
- Lymphocytes circulate through the blood and home to lymph nodes, spleen, tonsils, adenoids, and Peyer's patches, the peripheral (secondary) lymphoid tissues.

Lymph nodes

- Within several days of antigenic stimulation, the primary follicles enlarge (follicular hyperplasia)
- Develop pale-staining germinal centers (secondary follicle) surrounded by a collar of resting naïve B cells (mantle zone)
- B cells acquire the capacity to make high-affinity antibodies against specific antigens in the germinal centers
- BCL2 negative

Germinal center histology

- Germinal centers are normally polarized, consisting of two distinct regions:
- (1) a dark zone containing proliferating blastlike B cells (centroblasts)
- (2) a light zone composed of B cells with irregular or cleaved nuclear contours (centrocytes).
- Interspersed between the germinal centers are antigen-presenting follicular dendritic cells and tingible body macrophages that contain nuclear remnants of apoptotic B cells.

Lymph nodes

- Paracortical T-cell zones may also undergo hyperplasia.
- Contain immunoblasts.
- The expanded T-cell zones encroach on and, in particularly exuberant reactions, efface the B-cell follicles.
- Sinus histiocytosis (reticular hyperplasia)
- Lymphatic endothelial cells
- and macrophages increased in numbers

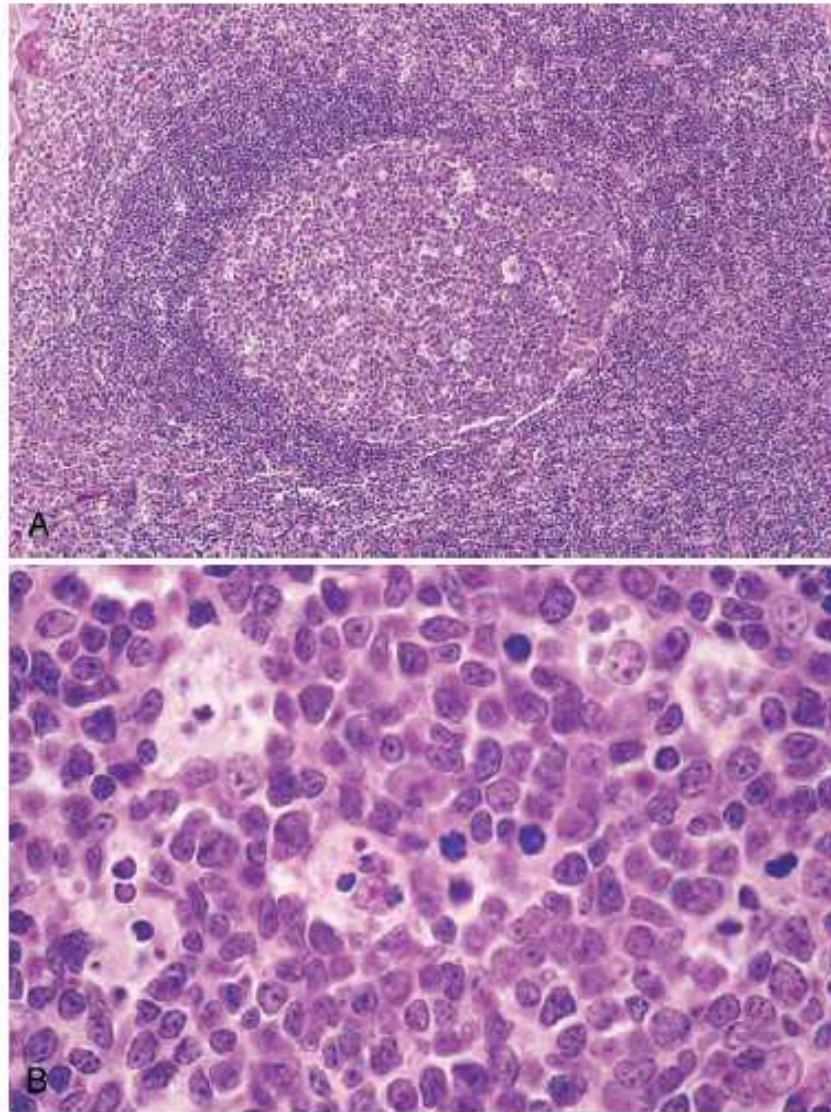


Figure 13-3 Follicular hyperplasia. **A**, Low-power view showing a reactive follicle and surrounding mantle zone. The dark-staining mantle zone is more prominent adjacent to the germinal-center light zone in the left half of the follicle. The right half of the follicle consists of the dark zone. **B**, High-power view of the dark zone shows several mitotic figures and numerous macrophages containing phagocytosed apoptotic cells (tingible bodies).

Hemophagocytic lymphohistiocytosis

- Macrophage activation syndrome
- Reactive condition related to macrophage and CD8+ cell activation
- The activated macrophages phagocytose blood cell progenitors in the marrow and formed elements in the peripheral tissues
- Suppress hematopoiesis
- Produce cytokine storm
- Acute febrile illness with hepatosplenomegaly
- Plasma ferritin and IL-2R elevated in severe disease
- There is a familial form

Table 13-4 World Health Organization Classification of Lymphoid Neoplasms

I. Precursor B-Cell Neoplasms
B-cell acute lymphoblastic leukemia/lymphoma (B-ALL)
II. Peripheral B-Cell Neoplasms
Chronic lymphocytic leukemia/small lymphocytic lymphoma B-cell prolymphocytic leukemia Lymphoplasmacytic lymphoma Splenic and nodal marginal zone lymphomas Extranodal marginal zone lymphoma Mantle cell lymphoma Follicular lymphoma Marginal zone lymphoma Hairy cell leukemia Plasmacytoma/plasma cell myeloma Diffuse large B-cell lymphoma Burkitt lymphoma
III. Precursor T-Cell Neoplasms
T-cell acute lymphoblastic leukemia/lymphoma (T-ALL)
IV. Peripheral T-Cell and NK-Cell Neoplasms
T-cell prolymphocytic leukemia Large granular lymphocytic leukemia Mycosis fungoides/Sézary syndrome Peripheral T-cell lymphoma, unspecified Anaplastic large-cell lymphoma Angioimmunoblastic T-cell lymphoma Enteropathy-associated T-cell lymphoma Panniculitis-like T-cell lymphoma Hepatosplenic $\gamma\delta$ T-cell lymphoma Adult T-cell leukemia/lymphoma Extranodal NK/T-cell lymphoma NK-cell leukemia
V. Hodgkin Lymphoma
Classical subtypes Nodular sclerosis Mixed cellularity Lymphocyte-rich Lymphocyte depletion Lymphocyte predominance

NK, Natural killer.

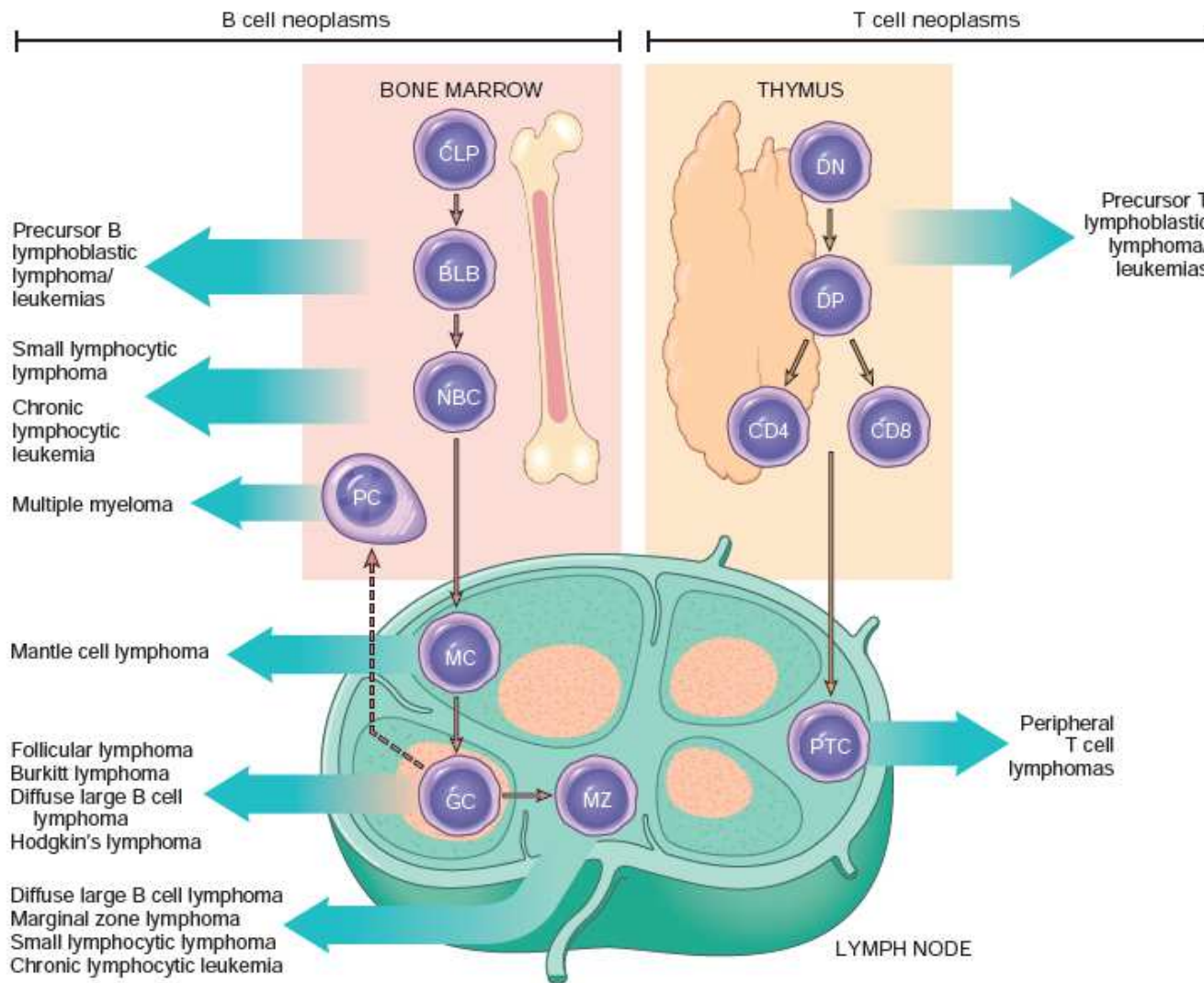


Figure 13-5 Origin of lymphoid neoplasms. Stages of B- and T-cell differentiation from which specific lymphoid tumors emerge are shown. CLP, Common lymphoid precursor; BLB, pre-B lymphoblast; DN, CD4/CD8 double-negative pro-T cell; DP, CD4/CD8 double-positive pre-T cell; GC, germinal-center B cell; MC, mantle B cell; MZ, marginal zone B cell; NBC, naive B cell; PTC, peripheral T cell.

Lymphoid disorders

- Antigen receptor gene rearrangement generally precedes transformation of lymphoid cells
- All daughter cells derived from the malignant progenitor share the same antigen receptor gene configuration and sequence, and synthesize identical antigen receptor proteins (either immunoglobulins or T-cell receptors).
- 85-90% are B-cell neoplasms
- Often associated with immune abnormalities
- Neoplastic B and T cells tend to recapitulate the homing behavior of their normal counterparts

Table 13-5 Some Immune Cell Antigens Detected by Monoclonal Antibodies

Antigen Designation	Normal Cellular Distribution
Primarily T-Cell Associated	
CD1	Thymocytes and Langerhans cells
CD3	Thymocytes, mature T cells
CD4	Helper T cells, subset of thymocytes
CD5	T cells and a small subset of B cells
CD8	Cytotoxic T cells, subset of thymocytes, and some NK cells
Primarily B-Cell Associated	
CD10	Pre-B cells and germinal-center B cells
CD19	Pre-B cells and mature B cells but not plasma cells
CD20	Pre-B cells after CD19 and mature B cells but not plasma cells
CD21	EBV receptor; mature B cells and follicular dendritic cells
CD23	Activated mature B cells
CD79a	Marrow pre-B cells and mature B cells
Primarily Monocyte or Macrophage Associated	
CD11c	Granulocytes, monocytes, and macrophages; also expressed by hairy cell leukemias
CD13	Immature and mature monocytes and granulocytes
CD14	Monocytes
CD15	Granulocytes; Reed-Sternberg cells and variants
CD33	Myeloid progenitors and monocytes
CD64	Mature myeloid cells
Primarily NK-Cell Associated	
CD16	NK cells and granulocytes
CD56	NK cells and a subset of T cells
Primarily Stem Cell and Progenitor Cell Associated	
CD34	Pluripotent hematopoietic stem cells and progenitor cells of many lineages
Activation Markers	
CD30	Activated B cells, T cells, and monocytes; Reed-Sternberg cells and variants
Present on All Leukocytes	
CD45	All leukocytes; also known as leukocyte common antigen (LCA)

CD, Cluster designation; EBV, Epstein-Barr virus; NK, natural killer.

Lymphoid disorders

- Lymphoblastic lymphomas are neoplasms composed of immature B (pre-B) or T (pre-T) cells
- 85% B-cell
- Loss of function of PAX5, E2A, and EBF, or a balanced t(12;21) involving the genes ETV6 and RUNX1
- Thymic (T-cell) lymphoma, peaks in adolescence
- 70% gain of function NOTCH mutation

Table 13-6 Summary of Major Types of Lymphoid Leukemias and Non-Hodgkin Lymphomas

Diagnosis	Cell of Origin	Genotype	Salient Clinical Features
Neoplasms of Immature B and T Cells			
B-cell acute lymphoblastic leukemia/lymphoma*	Bone marrow precursor B cell	Diverse chromosomal translocations; t(12;21) involving <i>RUNX1</i> and <i>ETV6</i> present in 25%	Predominantly children; symptoms relating to marrow replacement and pancytopenia; aggressive
T-cell acute lymphoblastic leukemia/lymphoma	Precursor T cell (often of thymic origin)	Diverse chromosomal translocations, <i>NOTCH1</i> mutations (50%-70%)	Predominantly adolescent males; thymic masses and variable bone marrow involvement; aggressive
Neoplasms of Mature B Cells			
Burkitt lymphoma*	Germinal-center B cell	Translocations involving <i>MYC</i> and Ig loci, usually t(8;14); subset EBV-associated	Adolescents or young adults with extranodal masses; uncommonly presents as "leukemia"; aggressive
Diffuse large B-cell lymphoma†	Germinal-center or postgerminal center B cell	Diverse chromosomal rearrangements, most often of <i>BCL6</i> (30%), <i>BCL2</i> (10%), or <i>MYC</i> (5%)	All ages, but most common in older adults; often appears as a rapidly growing mass; 30% extranodal; aggressive
Extranodal marginal zone lymphoma	Memory B cell	t(11;18), t(1;14), and t(14;18) creating <i>MALT1-IAP2</i> , <i>BCL10-IgH</i> , and <i>MALT1-IgH</i> fusion genes, respectively	Arises at extranodal sites in adults with chronic inflammatory diseases; may remain localized; indolent
Follicular lymphoma†	Germinal-center B cell	t(14;18) creating <i>BCL2-IgH</i> fusion gene	Older adults with generalized lymphadenopathy and marrow involvement; indolent
Hairy cell leukemia	Memory B cell	Activating <i>BRAF</i> mutations	Older males with pancytopenia and splenomegaly; indolent
Mantle cell lymphoma	Naive B cell	t(11;14) creating <i>CyclinD1-IgH</i> fusion gene	Older males with disseminated disease; moderately aggressive
Multiple myeloma/solitary plasmacytoma†	Post-germinal-center bone marrow homing plasma cell	Diverse rearrangements involving <i>IgH</i> , 13q deletions	Myeloma: older adults with lytic bone lesions, pathologic fractures, hypercalcemia, and renal failure; moderately aggressive Plasmacytoma: isolated plasma cell masses in bone or soft tissue; indolent
Small lymphocytic lymphoma/chronic lymphocytic leukemia	Naive B cell or memory B cell	Trisomy 12, deletions of 11q, 13q, and 17p	Older adults with bone marrow, lymph node, spleen, and liver disease; autoimmune hemolysis and thrombocytopenia in a minority; indolent
Neoplasms of Mature T Cells or NK Cells			
Adult T-cell leukemia/lymphoma	Helper T cell	HTLV-1 provirus present in tumor cells	Adults with cutaneous lesions, marrow involvement, and hypercalcemia; occurs mainly in Japan, West Africa, and the Caribbean; aggressive
Peripheral T-cell lymphoma, unspecified	Helper or cytotoxic T cell	No specific chromosomal abnormality	Mainly older adults; usually presents with lymphadenopathy; aggressive
Anaplastic large-cell lymphoma	Cytotoxic T cell	Rearrangements of <i>ALK</i> (anaplastic large cell lymphoma kinase) in a subset	Children and young adults, usually with lymph node and soft-tissue disease; aggressive
Extranodal NK/T-cell lymphoma	NK-cell (common) or cytotoxic T cell (rare)	EBV-associated; no specific chromosomal abnormality	Adults with destructive extranodal masses, most commonly sinonasal; aggressive
Mycosis fungoides/Sézary syndrome	Helper T cell	No specific chromosomal abnormality	Adult patients with cutaneous patches, plaques, nodules, or generalized erythema; indolent
Large granular lymphocytic leukemia	Two types: cytotoxic T cell and NK cell	Point mutations in <i>STAT3</i>	Adult patients with splenomegaly, neutropenia, and anemia, sometimes accompanied by autoimmune disease

*Most common tumors in children

†Most common tumors in adults.

EBV, Epstein-Barr virus; *HIV*, human immunodeficiency virus; *Ig*, immunoglobulin; *NK*, natural killer.

Small cell lymphoma

- Median age 60 years old.
- Twice as frequent in men.
- Often asymptomatic.
- When symptoms appear, they are nonspecific and include easy fatigability, weight loss, and anorexia.
- Gradual enlargement of all lymph nodes.
- 50-60%, generalized lymphadenopathy and hepatosplenomegaly
- Chronic Lymphocytic Leukemia if lymphocytosis. .

Small cell lymphoma

- Lymph nodes are effaced.
- Admixed are variable numbers of larger activated lymphocytes that often gather in loose aggregates referred to as proliferation centers, which contain mitotically active cells.
- Proliferation centers are pathognomonic
- Richter syndrome
- 5-10% will transform to diffuse large B-cell lymphoma
- Rapidly enlarging mass within lymph node or spleen
- Rapidly fatal

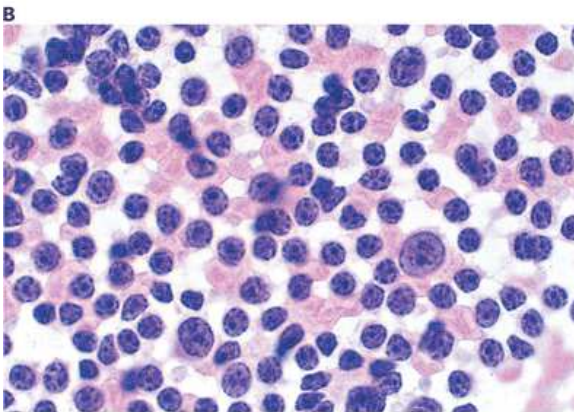
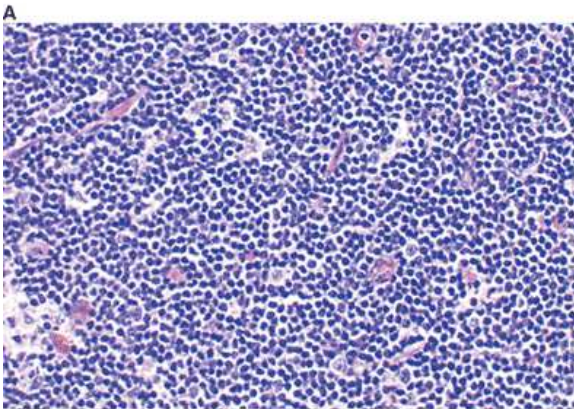
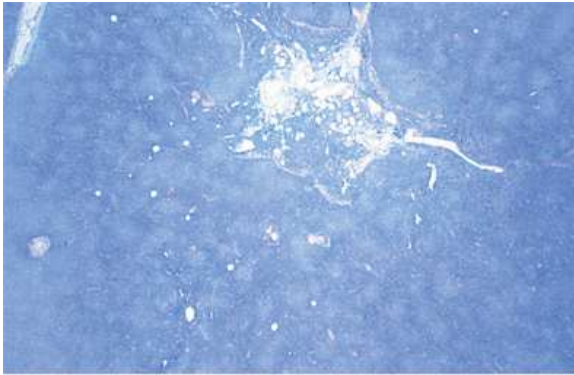
SLL STAGING SYSTEM

Lugano Modification of Ann Arbor Staging System^d (for primary nodal lymphomas)

<u>Stage^e</u>	<u>Involvement^g</u>	<u>Extranodal (E) Status</u>
<i>Limited</i>		
Stage I	One node or a group of adjacent nodes	Single extranodal lesions without nodal involvement
Stage II	Two or more nodal groups on the same side of the diaphragm	Stage I or II by nodal extent with limited contiguous extranodal involvement
Stage II bulky ^f	II as above with “bulky” disease	Not applicable
<i>Advanced</i>		
Stage III ^h	Nodes on both sides of the diaphragm	Not applicable
	Nodes above the diaphragm with spleen involvement	
Stage IV ^h	Additional non-contiguous extralymphatic involvement	Not applicable

Reprinted with permission. © 2014 American Society of Clinical Oncology. All rights reserved. Cheson B, Fisher R, Barrington S, et al. Recommendations for Initial Evaluation, Staging and Response Assessment of Hodgkin and Non-Hodgkin Lymphoma – the Lugano Classification. J Clin Oncol 2014;32:3059-3068.

Small cell lymphoma



A. At low-power magnification, numerous pale nodules are seen; these represent proliferation centers (pseudofollicles). B. In this field, neoplastic small lymphocytes diffusely replace architecture. C. Imprint preparation of lymph node involved by SLL, showing many small round lymphocytes with few paraimmunoblasts. (A, B, C, H&E; A, x20; B, x400; C, x1000.)

Source: Kantarjian HM, Wolff RA, Koller CA: *MD Anderson Manual of Medical Oncology*: <http://www.accessmedicine.com>

Copyright © The McGraw-Hill Companies, Inc. All rights reserved.

Fig. 5-6 Accessed 04/27/2010

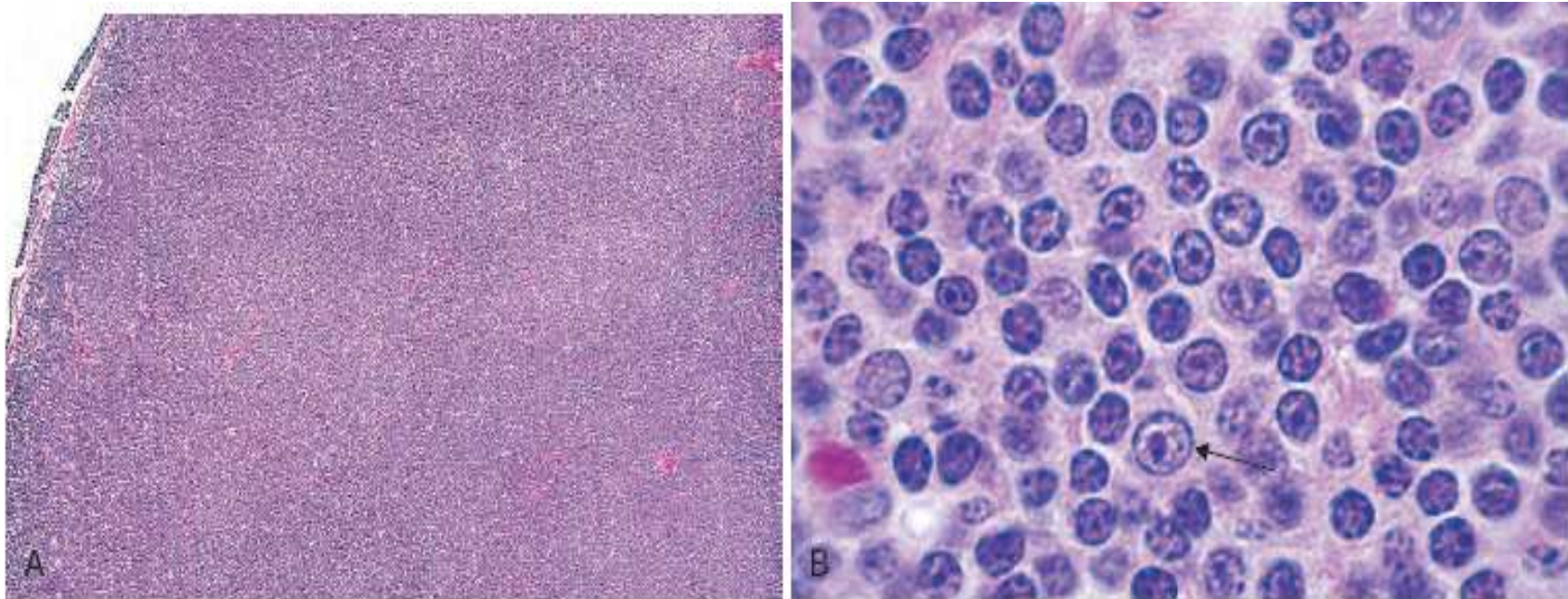


Figure 13-7 Small lymphocytic lymphoma/chronic lymphocytic leukemia (lymph node). **A**, Low-power view shows diffuse effacement of nodal architecture. **B**, At high power the majority of the tumor cells are small round lymphocytes. A "prolymphocyte," a larger cell with a centrally placed nucleolus, is also present in this field (*arrow*). (A, Courtesy Dr. José Hernandez, Department of Pathology, University of Texas Southwestern Medical School, Dallas, Texas.)

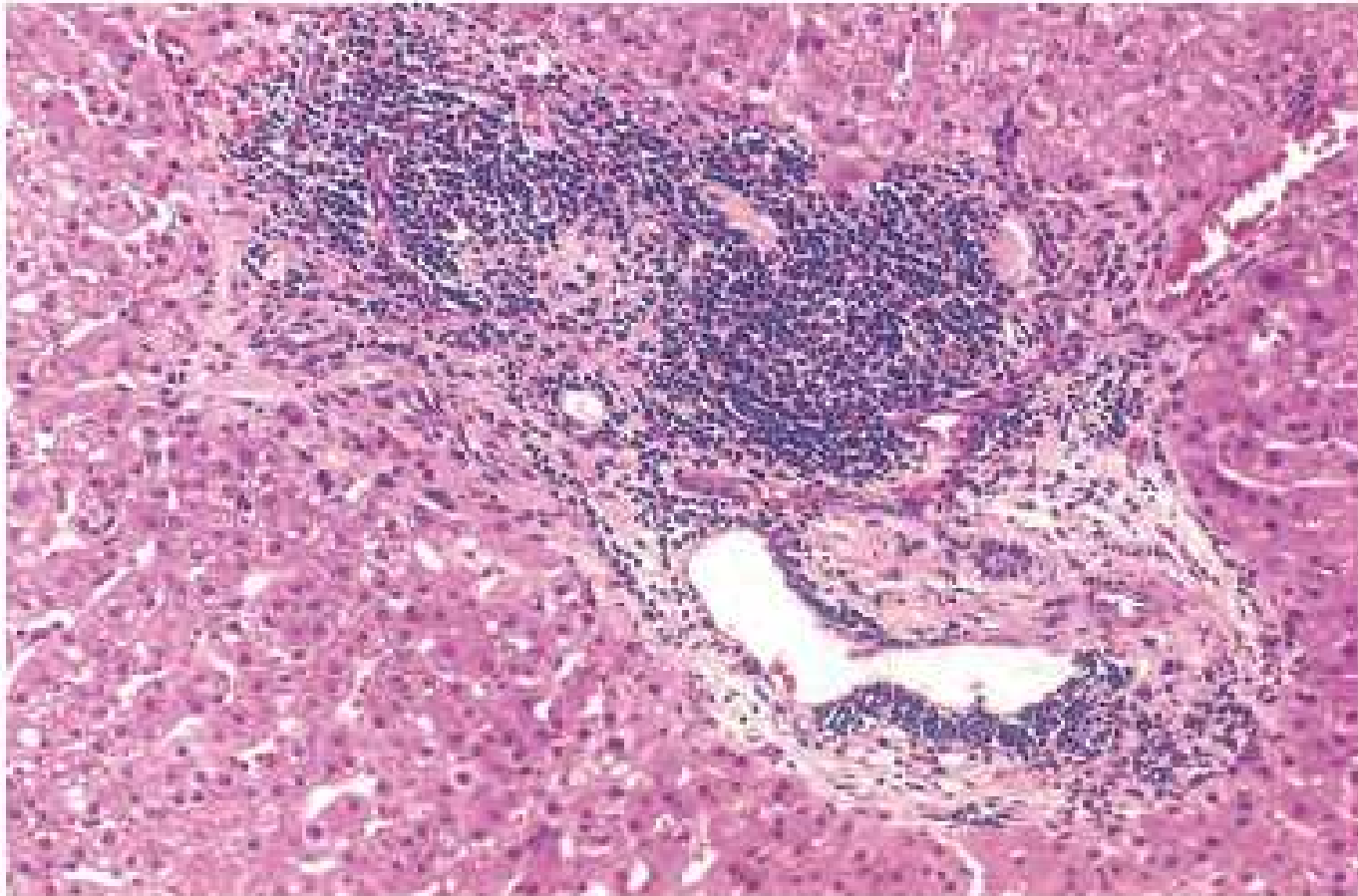


Figure 13-9 Small lymphocytic lymphoma/chronic lymphocytic leukemia involving the liver. Low-power view of a typical periportal lymphocytic infiltrate. (Courtesy Dr. Mark Fleming, Department of Pathology, Children's Hospital, Boston, Mass.)

Lymphoplasmacytic lymphoma

- Waldenström's macroglobulinemia
- >60 years of age
- Europeans, principally
- Anemia and thrombocytopenia
- Weight loss and night sweats
- IgM and β_2 -microglobulin elevated
- IgM may cause red blood cell aggregation (rouleaux formation) and increase red cell internal viscosity
- IgM binding of clotting factors and cryoglobulinemia causing Raynaud phenomena and cold urticaria

Lymphoplasmacytic lymphoma

- 15-30%, hyperviscosity (IgM >3g/dL)
- Oronasal bleeding, headache, visual disturbances due to retinal bleeding, and dizziness
- 10%, cold agglutinins
- Progress to diffuse large B-cell lymphoma with immunoblasts
- Primary amyloidosis

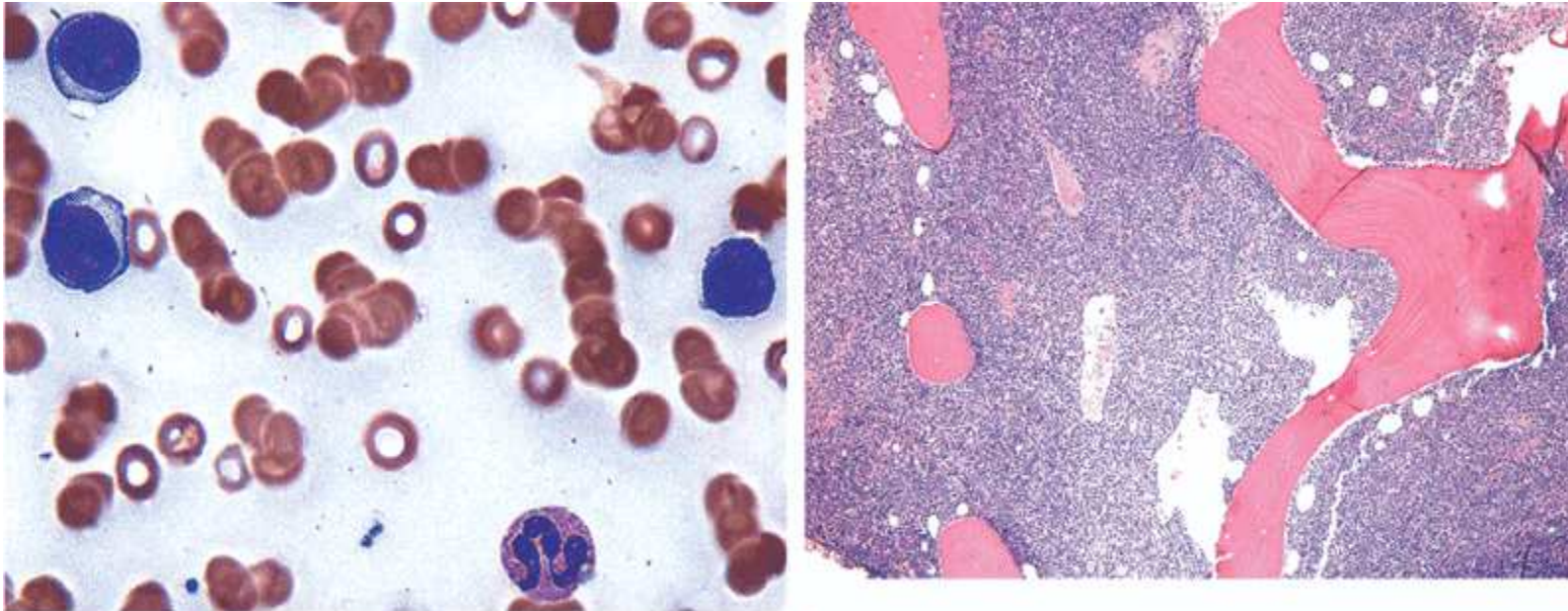
Lymphoplasmacytic lymphoma

- 90%, MYD88 mutation at 3p22.2
- TLR, IL1R signaling
- Triggers BTK
- Activates NF-kB
- 30% also have CXCR4 mutation as well
- B cells home to bone marrow
- Associated with hyperviscosity syndrome
- Related to disease progression

Lymphoplasmacytic lymphoma

- 60%, del 6
- TNF- α induced protein and B lymphocyte induced maturation protein silenced
- 17%, ARID1A mutations
- IgM, CD19, CD20, CD22, CD79A, CD25 and CD38 frequently expressed
-
- Survival best with MYD88 mutation; CXCR4 mutation intermediate survival; MYD88 and CXC4 mutations poor survival

Lymphoplasmacytic lymphoma



B Fig. 5-12 Accessed 04/27/2010

Source: Kantarjian HM, Wolff RA, Koller CA: *MD Anderson Manual of Medical Oncology*; <http://www.accessmedicine.com>

Copyright © The McGraw-Hill Companies, Inc. All rights reserved.

A. In the aspirate smear, the neoplastic cells have abundant cytoplasm and eccentrically located nuclei suggestive of plasmacytoid differentiation. B. In the biopsy specimen, the neoplastic cells diffusely replace the medullary space. (A, Wright-Giemsa, x500; B, H&E, x400.)

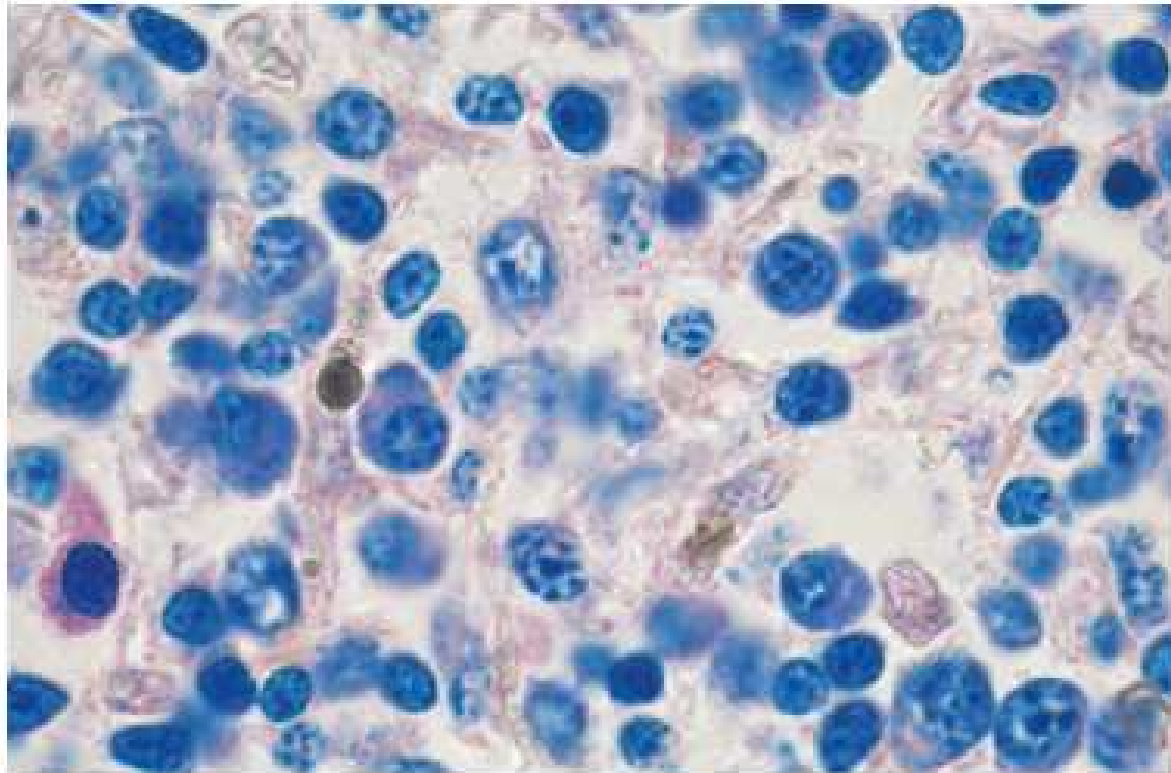


Figure 13-19 Lymphoplasmacytic lymphoma. Bone marrow biopsy shows a characteristic mixture of small lymphoid cells exhibiting various degrees of plasma cell differentiation. In addition, a mast cell with purplish red cytoplasmic granules is present at the left-hand side of the field.

Treatment of small cell and lymphoplasmacytic lymphoma

- Ibrutinib and acalabrutinib (Bruton tyrosine kinase inhibitors) improve progression-free survival when compared with chemoimmunotherapy
- Benefit extends across all prognostic groups.
- Time-limited therapy with venetoclax results in deep remissions with undetectable minimal residual disease in a high-proportion of treatment-naïve patients
- Ibrutinib-rituximab in relapsed/refractory Waldenström with or without CXCR4 mutation.
- BTK inhibition blocks macrophage activation; M2 is inducible; major adverse effect is atrial fibrillation

Plasma cell neoplasms

- Multiple myeloma
- Multiple lytic bone lesions associated with pathologic fractures
- Hypercalcemia
- Neoplastic plasma cells suppress normal humoral immunity and secrete partial immunoglobulins that are nephrotoxic
- Associated with diverse translocations involving the IgH locus
- Frequent dysregulation and overexpression of D cyclins

Other plasma cell neoplasms

- MGUS (monoclonal gammopathy of unknown significance):
- Common in older adults
- Progresses to myeloma at a rate of 1% per year
- Smoldering myeloma
- Disseminated disease that pursues an unusually indolent course
- Solitary osseous plasmacytoma
- Solitary bone lesion identical to disseminated myeloma
- Progress to myeloma within 7 to 10 years

Other plasma cell neoplasms

- Extramedullary plasmacytoma
- Solitary mass, usually in the upper aerodigestive tract
- Rarely progresses to systemic disease

Genetic characteristics of lymphomas

- t(11;14) bcl-1 mantle-cell lymphoma
- t(14;18) bcl-2 follicle center lymphoma most common
- t(9;22) bcr-abl chronic myelogenous leukemia
- t(18;14) c-myc Burkitt; small noncleaved (CNS involvement high)
- trisomy 3 extranodal disease (lymphoma)
- trisomy 12 CLL; small lymphocytic
- t(14;19) bcl-3 B-CLL
- t(3;22) bcl-6 large cell; small cleaved cell
- 14q11 tcl-1-3,5 T-ALL delta receptor rearrangement
- 7q35 tcl-4 T-ALL beta receptor rearrangement; lymphoblastic lymphoma
- t(2;5) anaplastic Ki (CNS involvement high)

Genetic characteristics of lymphomas

- Ig_H rearrangements 14q32 B-cell lymphoma
- Ig_K rearrangements 2p11 B-cell lymphoma
- $Ig_H/BCL1$ t(11;14)(q13;q32) Mantle cell lymphoma
- $Ig_H/BCL2$ t(14;18)(q32;q21) Follicular lymphoma
some DLCBL
- PAX/Ig_H t(19;14)(p13;q32) Lymphoplasmacytic lymphoma
- $AP12/MLT$ t(11;18)(q21;q21) Extranodal marginal zone lymphoma

Genetic characteristics of lymphomas

- BCL6 t(3;n)(q;27n) some DLCBL
- C-MYC t(8;12)(q24;n) Burkitt lymphoma
- TCR β 7q34 rearrangement T-cell lymphoma
- TCR γ 7q15 rearrangement T-cell lymphoma
- NPM/ALK t(2;5)(p23;q35) Anaplastic large cell lymphoma

Risk factors

- 2,4 D, organophosphates, benzene, carbon tetrachloride
- EBV and HCV cause B-cell clonal expansion (HCV with cryoglobulinemia)
- HTLV-1, 5% have adult T cell leukemia/lymphoma

Risk factors

- CD44 lymphocytes likely to disseminate
- Lack of HLA-DR poorer outcome as are abnormalities on 1, 7, 17
- p53 mutation associated with histologic transformation in follicular
- 3q may have better outcome

Indolent lymphoma

- Small lymphocytic; follicular
- Stage with CT abdomen/pelvis, CXR, bilateral bone marrow biopsies
- Minimal involvement in only one site may not be of major prognostic importance
- Elevated LDH, $\beta 2$ microglobulin; B symptoms, large tumor burden, older age, poor performance status are poor prognostic signs
- bcl-2 may be found in 80-90% patients, but no correlation with survival
- 10-15% patients present with I-II disease (10 yr survival post RT of 80%) with 10% relapsing 10 yrs post CR
- 4-6 yrs median time to progression
- no plateau on time to progression curve
- 6-10 year survivals

Indolent lymphomas

- PI3K is central signaling point in B-cell tumors.
- Activate BTK as well as AKT pathways.
- T_{regs} that express FOXP3 lead to production of CXCR 5 and turn off germinal center expression.
- The production of BCL6 augments production of T_{H} follicular cells.
- MYD88 mutated in Waldenstron's macroglobulinemia.
- Escapes apoptosis.
- Treat as in multiple myeloma.
- BTK inhibitor as well

Follicular lymphoma

- 20% of all lymphomas
- Painless adenopathy
- Extranodal involvement is uncommon
- Median survival is 7 years
- 35-50% transform to diffuse large B-cell lymphoma
- If MYC mutation present, may transform to a “Burkitt-like” lymphoma
- Median survival following transformation is 1 year

Follicular lymphoma

- Arise from germinal center
- t(14;18) translocation pathognomonic.
- Immunoglobulin heavy chain locus juxtaposed with BCL locus.
- Apoptosis antagonized.
- 90% of follicular lymphomas
- MLL2 mutation also found in 90%
- Histone methyltransferase
- CD19, CD20, CD10, surface Ig, and BCL6 expressed.
- 90% also express BCL2

Histopathology

- Uniform nodularity
- Small cleaved cells are in the majority in the lymph node.
- Peripheral blood involvement sufficient to produce lymphocytosis (usually less than 20,000/fl) is seen in about 10% of cases.
- This is not chronic lymphocytic leukemia
- Bone marrow involvement occurs in 85% of cases and characteristically takes the form of paratrabecular lymphoid aggregates.
- The splenic white pulp and hepatic portal triads are also frequently involved.

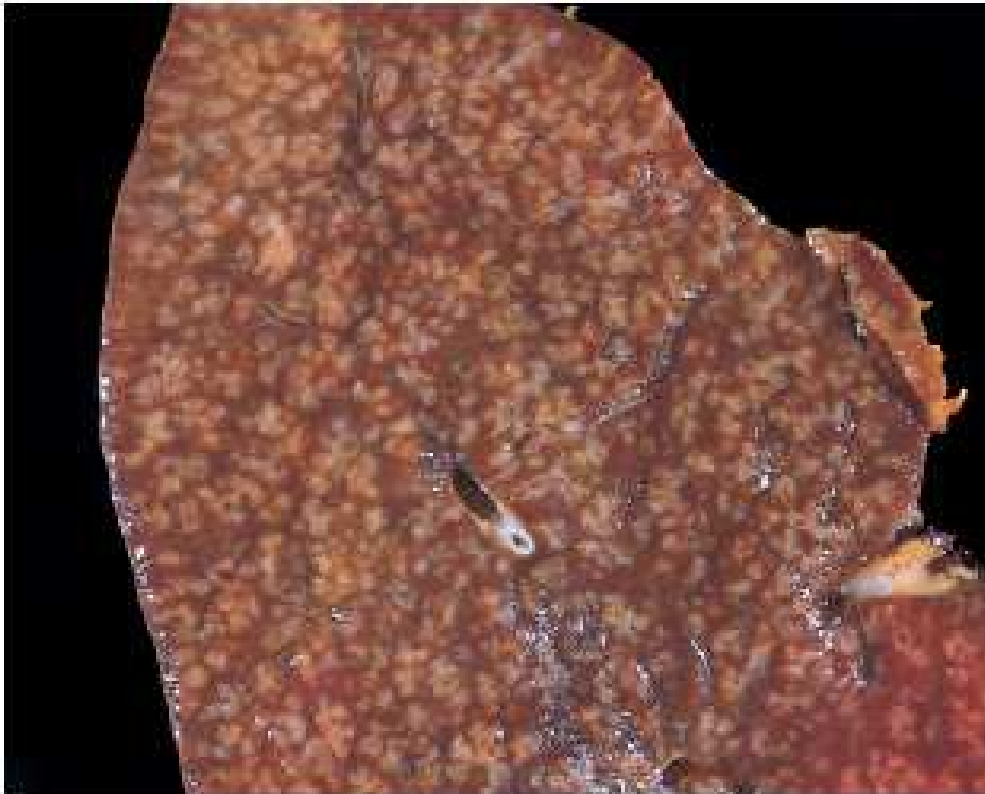
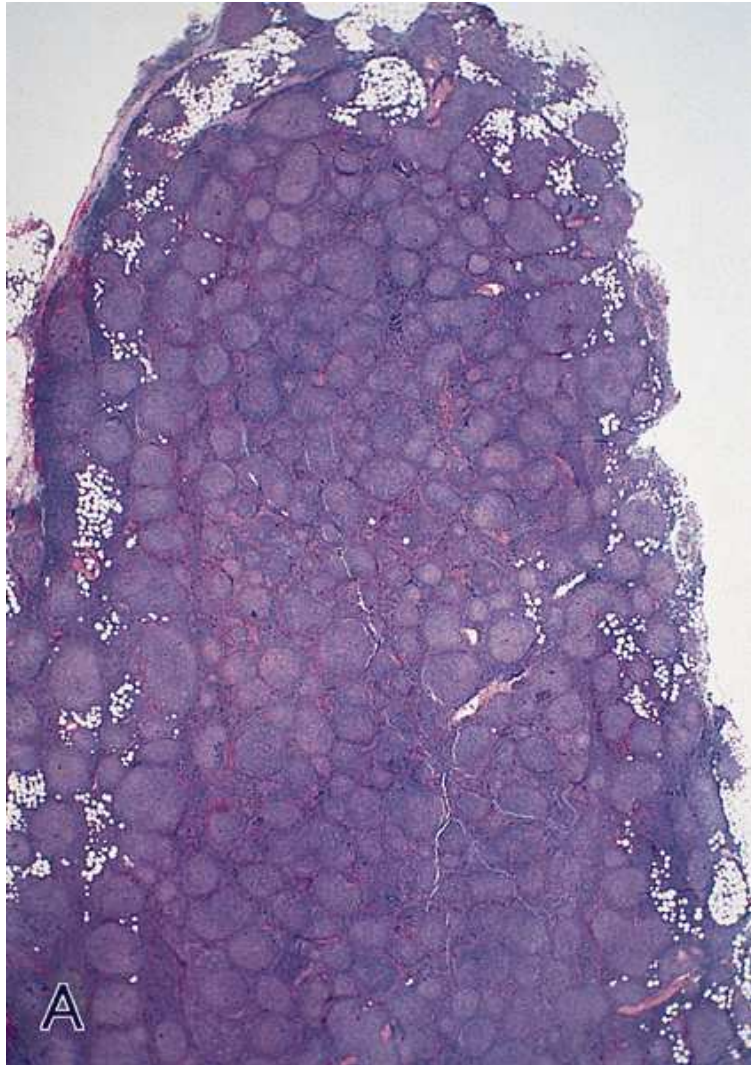


Figure 13-11 Follicular lymphoma (spleen). Prominent nodules represent white pulp follicles expanded by follicular lymphoma cells. Other indolent B-cell lymphomas (small lymphocytic lymphoma, mantle cell lymphoma, marginal zone lymphoma) can produce an identical pattern of involvement. (Courtesy Dr. Jeffrey Jorgenson, Department of Hematopathology, MD Anderson Cancer Center, Houston, Texas.)

Follicular lymphoma

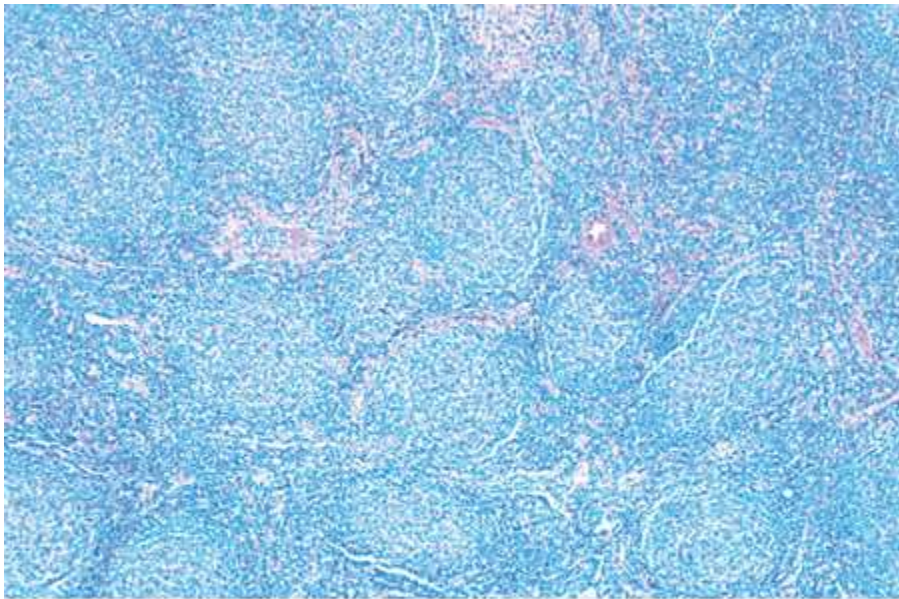


Demonstrated is a uniform nodularity throughout the lymph node with little variation in size and shape of the follicles which show a back-to-back arrangement. Follicles are also seen in the perinodal adipose tissue.

Fig. 6-1

Warnke, Roger A., Weiss, Lawrence M., Chan, John K. C., Cleary, Michael I., Dorfman, Ronald F., "Tumors of the lymph nodes and spleen," Atlas of Tumor Pathology. Third series. Fascicle 14. Armed forces Institute of Pathology, Washington, DC. (1995).

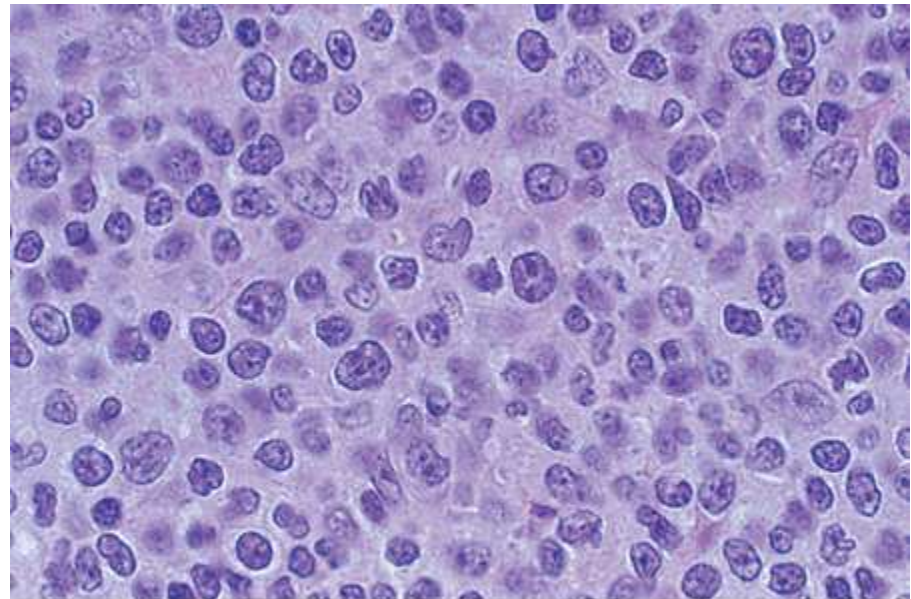
Follicular lymphoma



A

Source: Kantarjian HM, Wolff RA, Koller CA: *MD Anderson Manual of Medical Oncology*: <http://www.accessmedicine.com>

Copyright © The McGraw-Hill Companies, Inc. All rights reserved.



B

Source: Kantarjian HM, Wolff RA, Koller CA: *MD Anderson Manual of Medical Oncology*: <http://www.accessmedicine.com>

Copyright © The McGraw-Hill Companies, Inc. All rights reserved.

Fig. 5-1 Accessed 04/27/2010

A. The lymph node architecture is replaced by numerous neoplastic follicles. B. The neoplasm is composed of small cleaved and large noncleaved cells. (A, B, H&E; A, x100; B, x1000.)

MALT lymphoma

- Extranodal marginal zone (MALT) lymphoma
- 50% of gastric lymphomas.
- Associated with *H. pylori* infection.
- Low grade tumors that do not regress with treatment of *Helicobacter pylori* usually contain genetic abnormalities
- t(11,18) brings together the API2 (apoptosis-inhibitor 2) gene with the MLT (mutated in MALT lymphoma) gene.
 - The fusion protein is thought to inhibit apoptosis.
 - Most common mutation

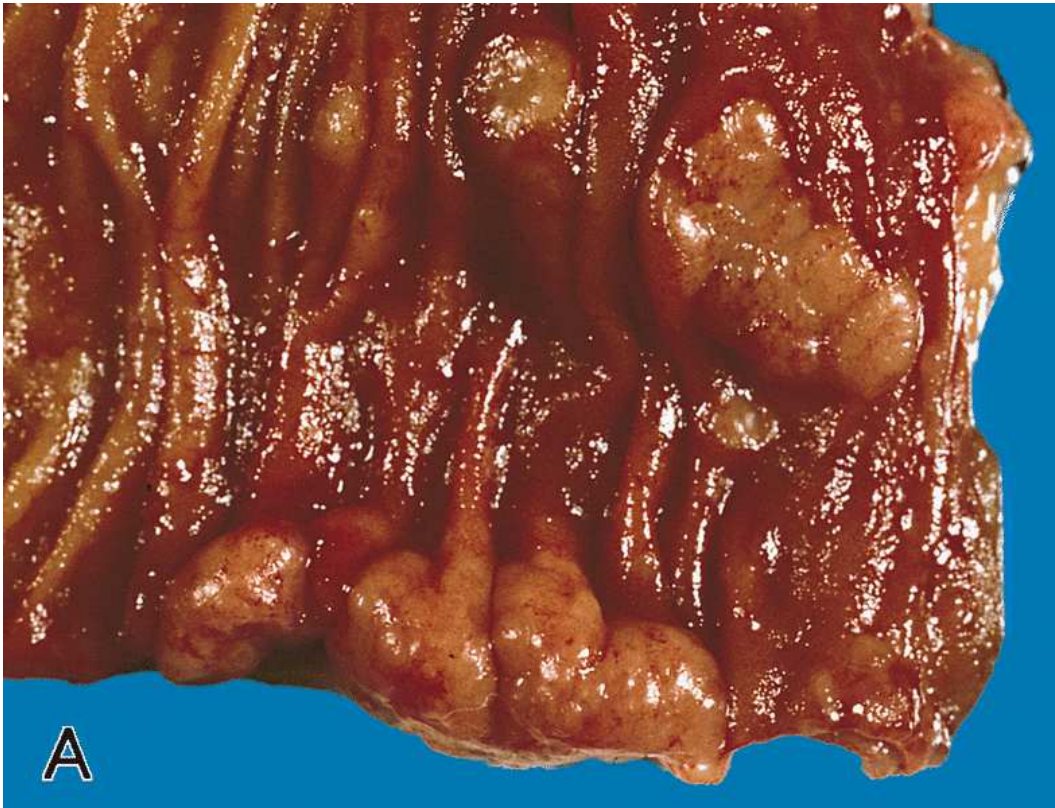MALT lymphoma

- Antigen dependent activation of NF- κ B in normal lymphocytes requires BCL10 and MLT.
- t(1;14) and t(14;18) translocations increase expression of BCL10 and MLT proteins respectively.
- p53 and p16 mutations may lead to transformation to diffuse large B-cell lymphoma.
- Cyclophosphamide, doxorubicin, vinblastine, prednisone, etoposide regimen followed by antibody to CD-20 is the treatment regimen.

MALT lymphoma

- Salivary glands are the most common sites of MALT lymphoma after the stomach.
- Sjögren's disease precedes MALT lymphoma in 83% of cases.
- No Helicobacter pylori association.
- Indolent
- May be treated with anti-CD20 antibody (rituximab) alone
- Age <60 years, low IPI score, and the presence of Sjögren's disease are associated with better outcomes.

MALT lymphoma

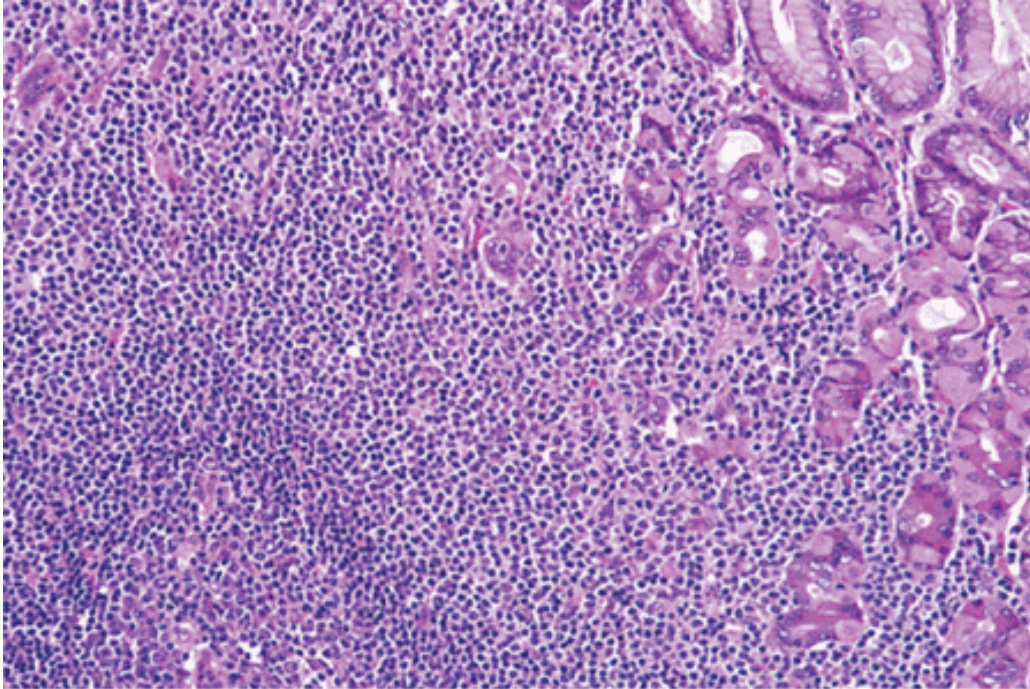


Numerous lymphomatous polyps vary from small expansions of the folds to larger nodules.

Fig. 8-7A

Riddell, RH, Petras, RE, Williams, GT, Sobin, LH., "Tumors of the intestines." Atlas of Tumor Pathology, Third Series, Fascicle 32. Armed Forces Institute of Pathology, Washington, D.C. 2003.

MALT lymphoma



The neoplasm partially replaces gastric mucosa and infiltrates epithelium. A reactive follicle is present at the bottom left of the field.

CD19 +, CD20+, CD5-, CD10-

25% CD43+; aids in diagnosis.

Source: Kantarjian HM, Wolff RA, Koller CA: *MD Anderson Manual of Medical Oncology*: <http://www.accessmedicine.com>

Copyright © The McGraw-Hill Companies, Inc. All rights reserved.

Fig. 5-7 Accessed 04/27/2010

Cutaneous lymphoma

- 20% of extranodal disease
- 25% of cutaneous lymphoma is of B-cell origin
- 10% of cutaneous lymphoma is a presentation of systemic disease
- 25% of extranodal disease will later manifest systemic involvement
- 69% present as T1 disease
- 53% recur following therapy

Mycosis fungoides

- Erythematous, often scaling plaques. May develop nodular lesions and spread systemically.
- Focal lichenoid tissue reaction.
- Sézary cells (CD4 +) characteristically form the bandlike infiltrate in the upper dermis.
- Pautrier micro-abscesses are single cells and small clusters that have invaded the epidermis.
- If generalized erythroderma, Sézary syndrome.
- Median survival is 10 years.
- May progress to systemic lymphoma.

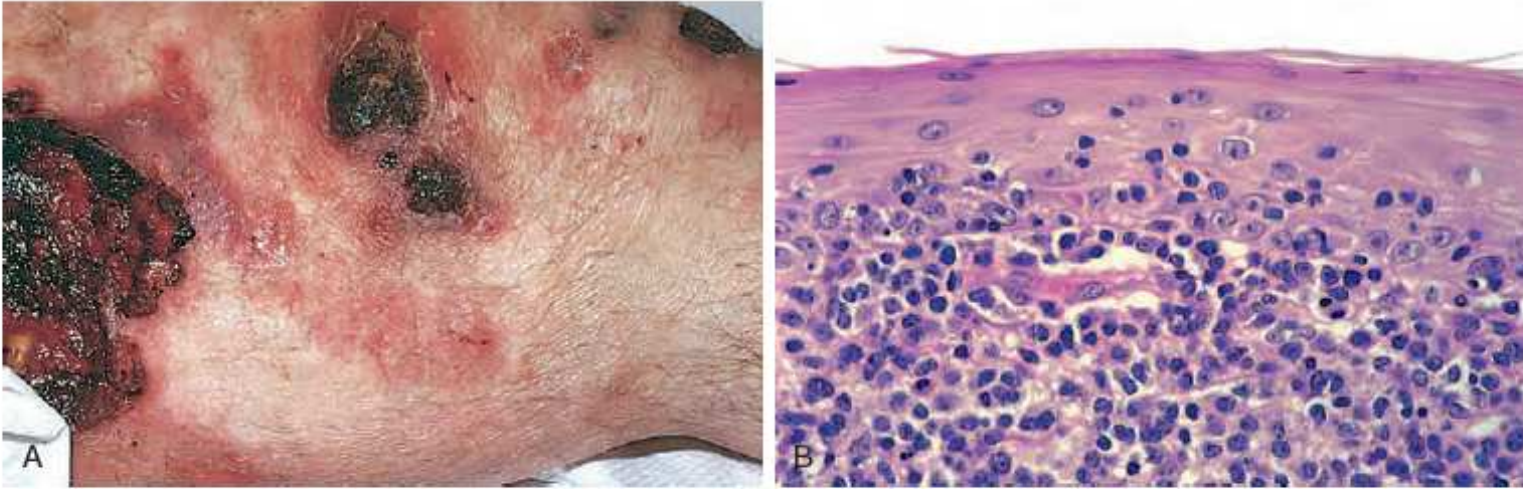
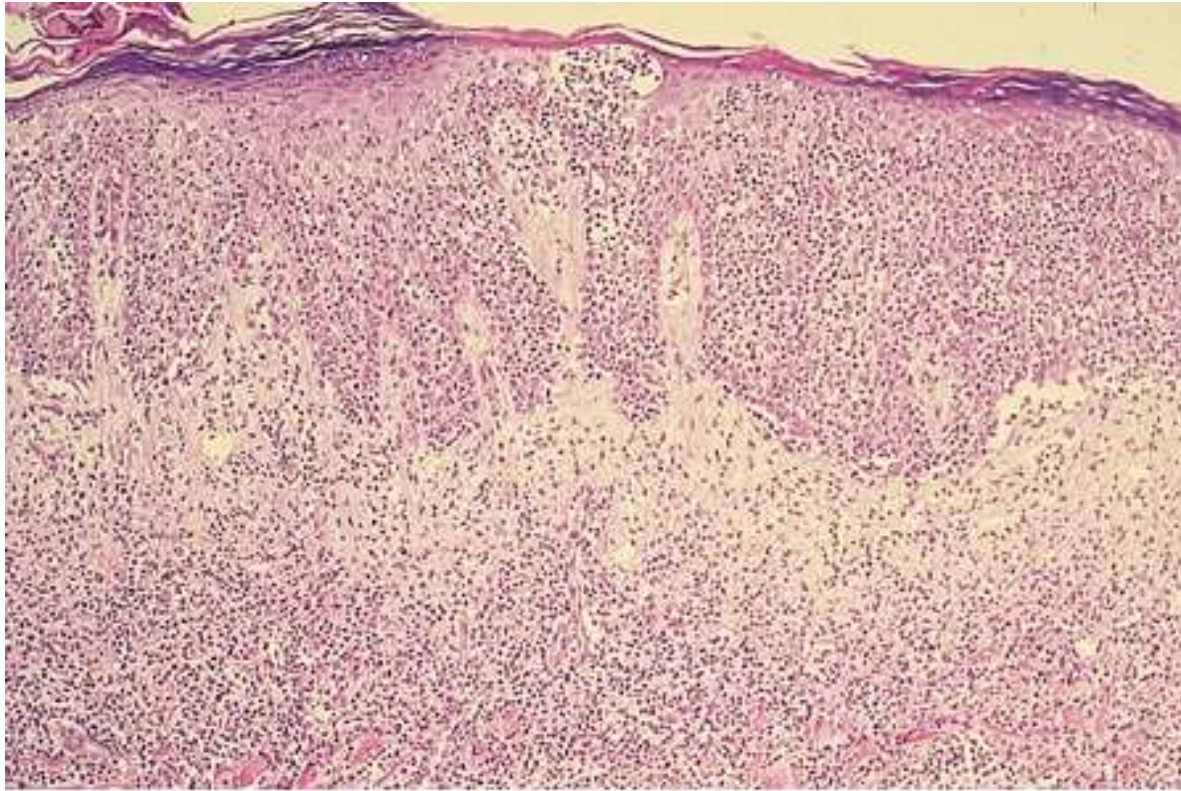


Figure 25-18 Cutaneous T-cell lymphoma. **A**, Several erythematous plaques with scaling and ulceration are evident. **B**, Microscopically, there is an infiltrate of atypical lymphocytes that accumulates beneath and invades the epidermis.

Mycosis fungoides



Source: Wolff K, Goldsmith LA, Katz SI, Gilchrest BA, Paller AS, Leffell DJ:
Fitzpatrick's Dermatology in General Medicine, 7th Edition: <http://www.accessmedicine.com>

Copyright © The McGraw-Hill Companies, Inc. All rights reserved.

Fig. 146-13
Accessed 07/20/2010

Aggressive lymphomas

- Mantle cell lymphoma (MCL)
- 5-7% of all lymphomas
- >60 years of age
- Presents as painless adenopathy
- 50% may have splenomegaly or GI complaints
- Polypoid submucosal tumor growths in the small bowel or colon (lymphomatoid polyposis)
- 20% may have peripheral blood involvement
- The blast variant has a propensity for CNS involvement.
- Has a short median survival of 3-5 years.
- Poor response to CHOP chemotherapy

Mantle cell lymphoma

- Express CD19, CD20 and is usually CD5+
- CD11c- and CD23-.
- 25% CD23+.
- Moderately high levels of surface immunoglobulin M expressed.
- IgH genes lack somatic hypermutation (naïve B-cell origin).
- IgM or IgD with κ or λ light chains
- 70% have t(11q32;14q32), transposing cyclin D1 gene to immunoglobulin gene
- Overexpress cyclin D1.

Aggressive lymphomas

- TP53, MYC independent predictors
- Hypermethylation is not a driving factor
- Conventional MCL (nodal presentation)
- Naïve B cells
- SOX11 mutation
- ATM driver mutation early
- CCND1/HES16
- RAG enzyme mediated
- APOBEC mutation
- SBS2 and SBS13 in kataegis and chromothripsis

Aggressive lymphomas

- Leukemic non-nodal MCL
- (a) Memory B cells
- No SOX11 mutation
- (b) 8%, mature B cells
- SHM/CSR mediation
- As with multiple myeloma (ALD/CSR), MTC repair region open
- ATM, CHK2 mutations

Aggressive lymphomas

- Clock like mutations in both types
- SBS1 and SBS5
- Non-canonical mutation
- SBS9
- Activates cytidine deaminase (AID)
- Canonical mutation
- SBS84
- Activates cytidine deaminase (AID)
- Immunoglobulin generated
- Non-nodal MCL

Histopathology

- Nodal tumor cells may surround reactive germinal centers to produce a nodular appearance at low power, or diffusely efface the node.
- Typically, the proliferation consists of a homogeneous population of small lymphocytes with irregular to occasionally deeply clefted (cleaved) nuclear contours
- Large cells resembling centroblasts and proliferation centers are absent.
- Occasionally, tumors composed of intermediate-sized cells with more open chromatin and a brisk mitotic rate are observed (“blast variant”)

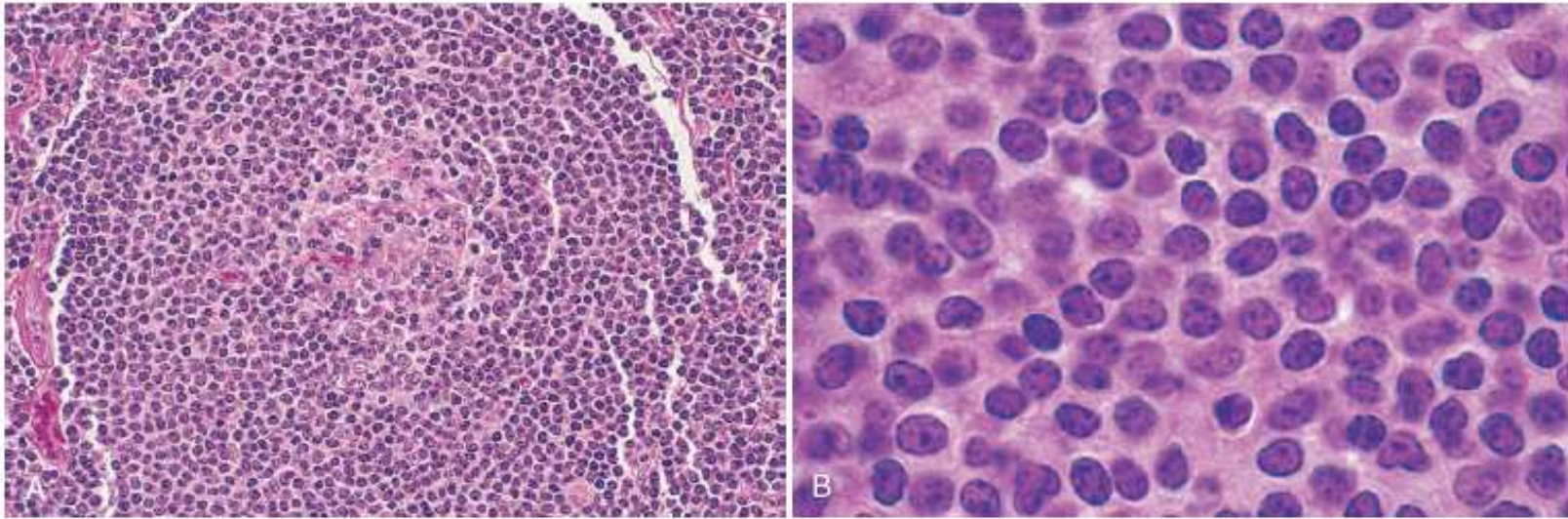
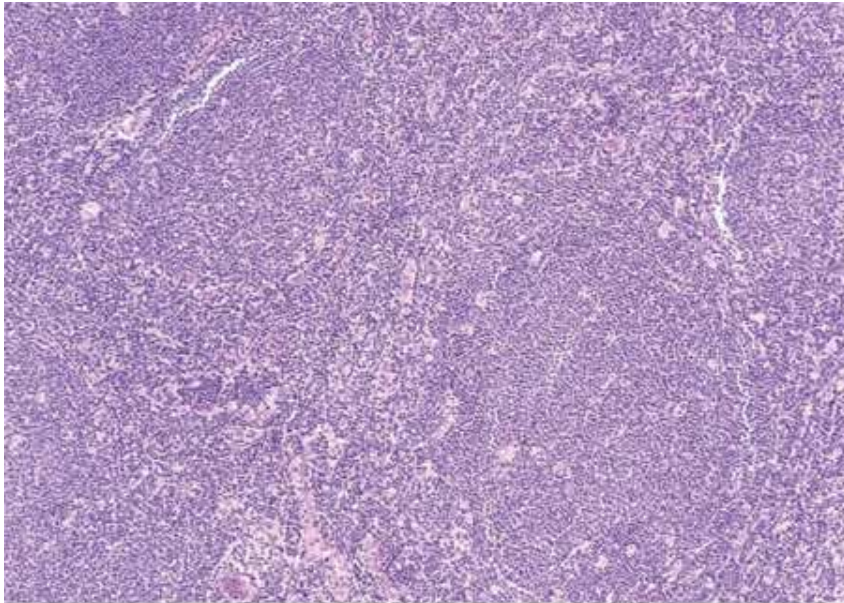


Figure 13-20 Mantle cell lymphoma. **A**, At low power, neoplastic lymphoid cells surround a small, atrophic germinal center, producing a mantle zone pattern of growth. **B**, High-power view shows a homogeneous population of small lymphoid cells with somewhat irregular nuclear outlines, condensed chromatin, and scant cytoplasm. Large cells resembling prolymphocytes (seen in chronic lymphocytic leukemia) and centroblasts (seen in follicular lymphoma) are absent.

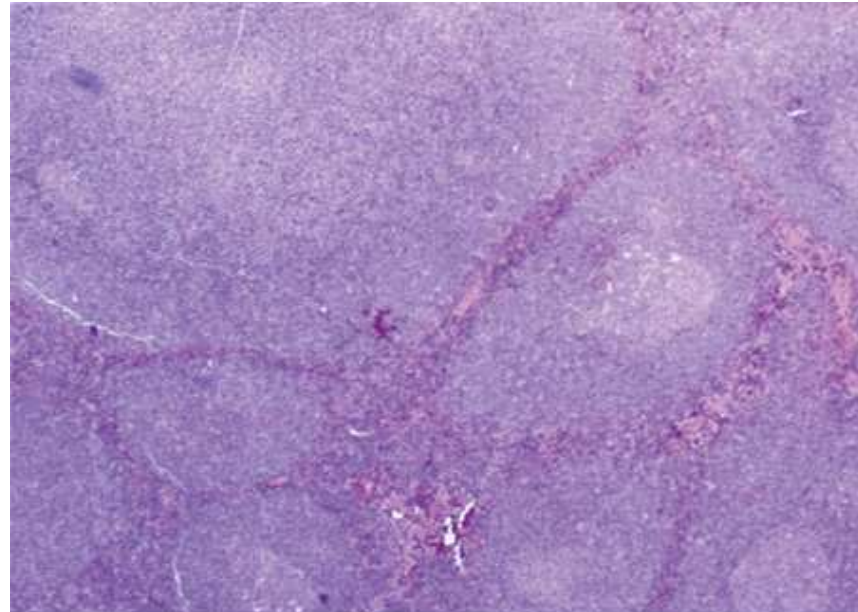
Mantle cell lymphoma



Source: Kantarjian HM, Wolff RA, Koller CA: *MD Anderson Manual of Medical Oncology*: <http://www.accessmedicine.com>

Copyright © The McGraw-Hill Companies, Inc. All rights reserved.

Left. Nodular pattern.



Source: Kantarjian HM, Wolff RA, Koller CA: *MD Anderson Manual of Medical Oncology*: <http://www.accessmedicine.com>

Copyright © The McGraw-Hill Companies, Inc. All rights reserved.

Right. Mantle zone pattern.

Figs. 6-18, 6-19. Accessed 04/27/2010

Aggressive lymphomas

- 25% of those with T-cell subtypes survive 5 years.
- 50% of those with diffuse large B cell lymphoma will have an overall survival of 5 years
 - 32% if extranodal
- HIV related lymphomas (EBV)
 - 70% are diffuse large B-cell lymphomas
 - Greater number of the remainder being Burkitt subtypes (MYC amplified).

Aggressive lymphomas

- Primary effusion lymphoma is HHV8 related
- HIV infected patients or the elderly
- IgH rearrangements found.
- Often in association with Hepatitis C infection

Diffuse large B-cell lymphoma

- 60 years of age
- 70%, nodal
- 30% of all lymphomas
- Germinal center B-cell type
- Derived from centroblast
- 33%, t(14;18)
- 30%, BCL6 mutation at 3q27
- DNA binding zinc-finger transcription repressor
- Overexpression both silences p53 and represses other factors that promote germinal center B-cell differentiation and apoptosis.

Diffuse large B-cell lymphoma

- 10-20%, EZH2 gene
- Histone methyltransferase
- Deletion of PTEN gene
- GCET, CD10, BCL6 +
- Good prognosis
- If CD5+, intermediate prognosis

Diffuse large B-cell lymphoma

- Activated B-cell type
- Arise from plasmablastic cells prior to germinal center exit
- 50%, NFkB
- 30%, MYD88
- 20%, CD79A or CD79B
- 10%, activating mutations of CARD11
- MUM1/IRF4, FOXP1, BCL2 +

Diffuse large B-cell lymphoma

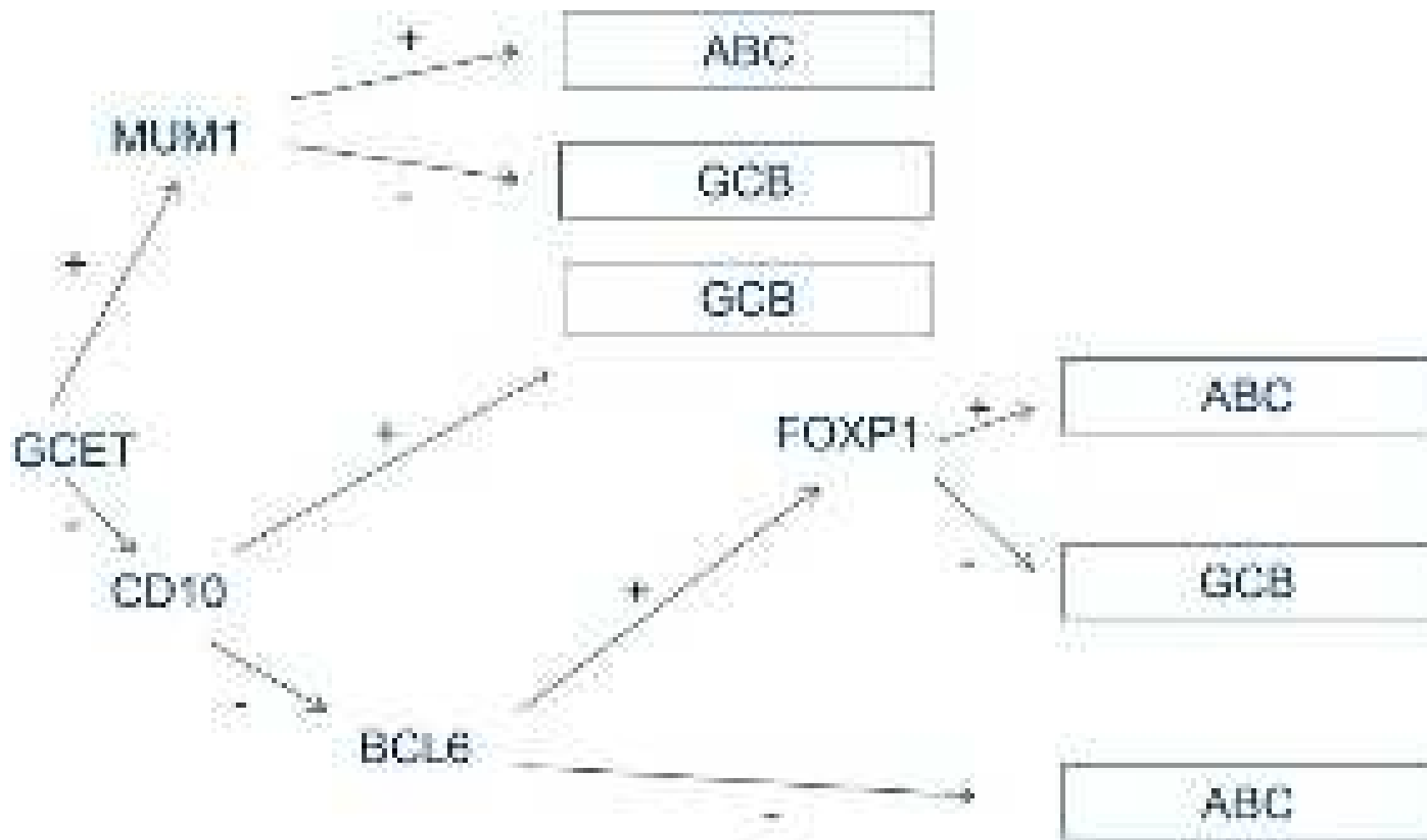
- Primary Mediastinal BCL
- Women 2:1
- 30-40 years of age
- Presents with anterosuperior mediastinal (thymic) mass
- Regional metastases
- IL4R mutations
- JAK2 amplification with STAT6 activation
- NF-kB activation with TRAF co-expression
- CD19, CD20, BCL6, MUM1/IRF4 +

Diffuse large B-cell lymphoma

- Not otherwise specified
- MYC amplification
- BCL2 overexpression
- MYC, BCL2
- MYC, BCL2, BCL6
- Do not respond to R-CHOP
- BTK inhibitor

Diffuse large B-cell lymphoma

- Primary CNS Lymphoma
- Aggressive malignancy
- Remains confined to the CNS, with rare cases of extra-CNS dissemination.-
- Stage IE disease (disease limited to a single extranodal organ)
- 95%, DLBCL morphology
- MYD88 and CD79 mutations



Choi algorithm has 80% concordance with genome expression

<https://www.ncbi.nlm.nih.gov/pmc/articles/PMC5725508/>

T-cell/histiocyte rich lymphoma

- 3% of all lymphomas
- Diffuse large B-cell lymphoma with non-neoplastic T-cells and histiocytes that obscure the neoplasm
- Part of the same spectrum of nodular lymphocyte predominant Hodgkins's disease
- Middle aged adults with advanced stage disease
- Fever, hepatosplenomegaly
- Intermediate prognosis

T-cell/histiocyte rich lymphoma

- Vaguely nodular pattern
- Near absence of B-cells in background
- Neoplastic cells surrounded by bland clusters of histiocytes
- LP-like (lymphocyte predominant-like):
- Pale and indistinct cytoplasm, lobated and vesicular nuclei resembling popcorn cells with small central nucleoli
- Background of small lymphocytes and often histiocytes
- No granulomas
- BCL6-, MUM1/IRF4+

T-cell/histiocyte rich lymphoma

- Centroblast-like:
- Pale eosinophilic cytoplasm, oval or round nuclei with vesicular chromatin and without nuclear atypia
- Small basophilic nucleoli adjacent to nuclear membrane
- HRS-like (Hodgkin Reed-Sternberg cell-like):
- Large multinucleated cells with abundant amphophilic cytoplasm, pleomorphic nuclei with prominent eosinophilic or amphophilic round and central nucleoli

Primary CNS lymphoma

- Primary CNS lymphoma
- Older patients as well as immunosuppressed patients
- Dissemination of the lymphoma within the brain, cranial nerves, leptomeninges, cerebrospinal fluid, intraocular structures, and spinal cord, without overt systemic disease
- Uniform infiltration by neoplastic B-lymphocytes.
- Angiocentric growth.
- Activated B-cell type
- Poor prognosis

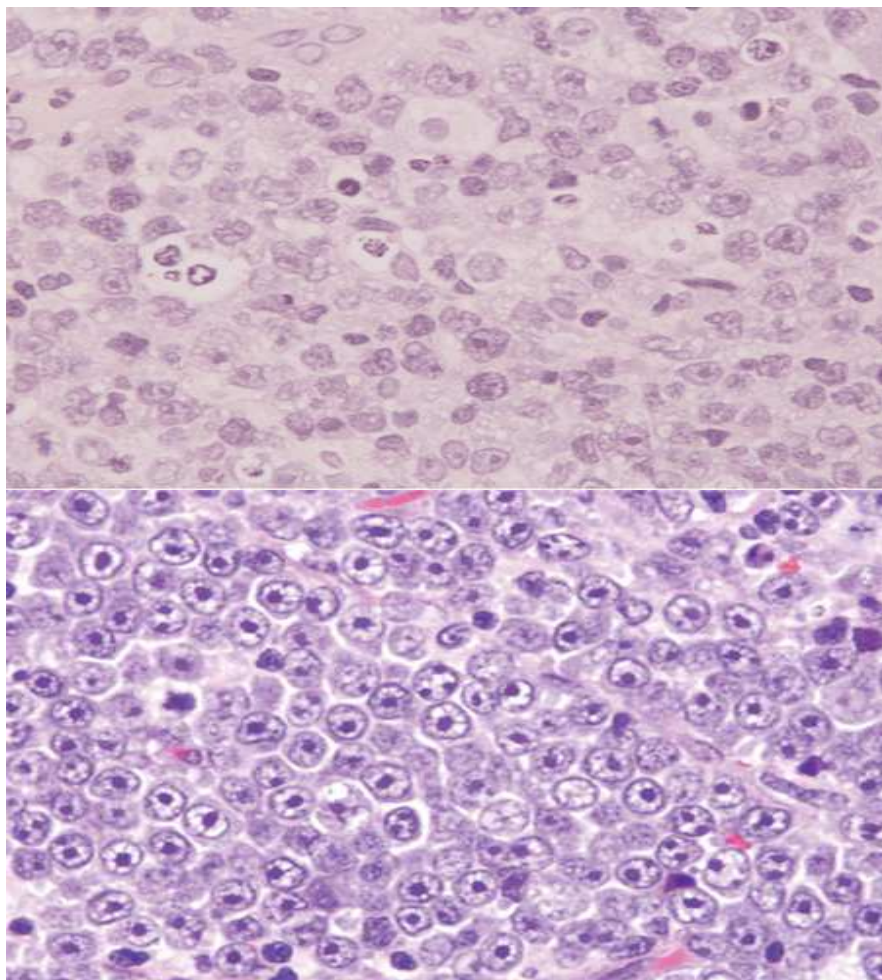
Primary CNS lymphoma

- High dose methotrexate induction followed by cytarabine and thiotepa with stem cell harvest
- High dose carmustine and thiotepa conditioning
- Stem cell transplant
- Whole brain radiotherapy
- Associated 5-year survival of >80%.
- If relapse, within 2 years.
- Steroid sensitive.

Primary lymphoma of the testis

- 1-2% of lymphomas
- >60 years of age
- Activated B-cell type
- Poor prognosis

Diffuse large B-cell lymphoma



Upper: The neoplastic cells are large with vesicular chromatin and are arranged in a diffuse pattern. (Hematoxylin-eosin, 1000x.)

Lower, immunoblastic variant. The neoplastic cells are large with prominent central nucleoli imparting a "target-like" appearance (hematoxylin-eosin, 1000x).

Source: Kantarjian HM, Wolff RA, Koller CA: *MD Anderson Manual of Medical Oncology*: <http://www.accessmedicine.com>

Copyright © The McGraw-Hill Companies, Inc. All rights reserved.
Copyright © The McGraw-Hill Companies, Inc. All rights reserved.

Figs. 6-3, 6-5 Accessed 04/27/2010

Aggressive NK-cell lymphoma

- No gender preference.
- 20 years of age
- 2-4 weeks median survival
- Fever, skin infiltration, lymphadenopathy and hepatosplenic involvement are common.
- Leukemic cells in the peripheral blood.
- Liver failure and DIC as late complications.

Aggressive NK-cell lymphoma

- Consist of either a mixture of small and large lymphoid cells or predominantly large lymphoid cells which contains large azurophilic granules resembling those observed in normal NK cells.
- Individual tumors contain identical EBV episomes.
- C-KIT mutations and epigenetic silencing of the tumor suppressor gene p73 (a homologue of p53) also contribute to the pathogenesis of this neoplasm.
- Fail to express CD21.
- CD3- and lack TCR rearrangements.
- Express NK cell markers.

Extranodal NK T-cell disease

- ENKTL, nasal type.
- 3% of non-Hodgkin lymphomas in Asia.
- Presents as a destructive midline mass involving the nasopharynx
- Less commonly, the skin or other extranodal sites such as the testis.
- The tumor cell infiltrate typically surrounds and invades small vessels, leading to extensive ischemic necrosis.
- EBV associated.

Extranodal NK T-cell disease

- Concurrent chemoradiotherapy with dexamethasone, etoposide, ifosfamide and carboplatin.
- High relapse rate.
- Transplant ineffective.

Hepatosplenic T-cell lymphoma

- Men
- 30 years of age.
- Hepatosplenomegaly but no lymphadenopathy.
- Immunosuppression as risk factor (but not EBV).
- Worst prognosis of peripheral T-cell lymphomas.

Hepatosplenic T-cell lymphoma

- CD4-, CD8- γ/δ preferentially exhibit homing to epithelial rich tissue and sinusoidal areas of the splenic pulp.
- Can mature outside of thymus.
- When activated, function as NK-cell-like.
- Doxorubicin, cytarabine, cisplatin, and pentostatin/alemtuzumab sequential chemotherapy.
- Allogeneic stem cell transplantation indicated.

Anaplastic large-cell lymphoma

- 24% of all T-cell lymphomas.
- Soft tissue involvement common.
- Occur in children and young adults.
- 66% ALK gene rearrangements at 2p23
- Constitutively activate Jak/STAT pathways).
- Some cells are large and contain horseshoe-shaped nuclei and voluminous cytoplasm (hallmark cells)
- Cluster about venules and infiltrate lymphoid sinuses.
- CD30 found only in tumor cells.

Anaplastic large-cell lymphoma

- Good response to chemotherapy if ALK positive.
- Cyclophosphamide, doxorubicin, vinblastine, etoposide, prednisone preferred regimen
- Brentuximab vedotin (anti-CD30 conjugated to monomethyl auristatin E) effective but with development of peripheral neuropathy.

Anaplastic large-cell lymphoma

- Ki/CD30 +, CD15/LeuM +
- Reed Sternberg cells also KiCD30+, CD15/LeuM+, but do not stain with T-cell or lymphocyte antibodies
- CD40+ as well as absence of t(2:5) distinguishes anaplastic large cell lymphoma from nodular Hodgkin's Disease

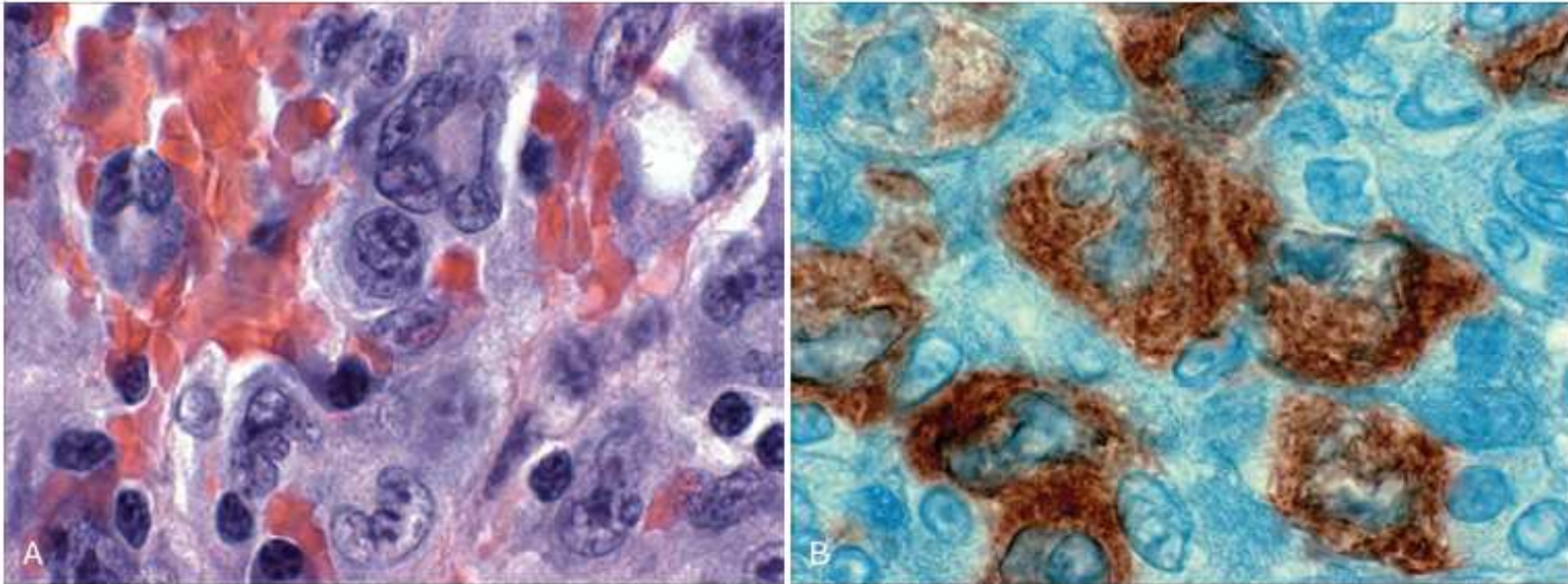


Figure 13-23 Anaplastic large-cell lymphoma. **A**, Several "hallmark" cells with horseshoe-like or "embryoid" nuclei and abundant cytoplasm lie near the center of the field. **B**, Immunohistochemical stain demonstrating the presence of ALK fusion protein. (Courtesy Dr. Jeffrey Kutok, Department of Pathology, Brigham and Women's Hospital, Boston, Mass.)

Peripheral T-cell lymphoma

- Panniculitis, occasionally accompanied by pruritis, fever, weight loss.
- Subcutaneous infiltration of T-lymphocytes.
- Mature T-cell phenotype expressed:
- CD3+, CD8+, CD56-, TCR rearrangements.
- Poor prognosis.
- T/NK cell lymphomas are strongly positive on PET scan.
- However, a negative PET during or following therapy in the ALK negative variant offers no prognostic information whereas in other lymphomas it is indicative of a complete response.

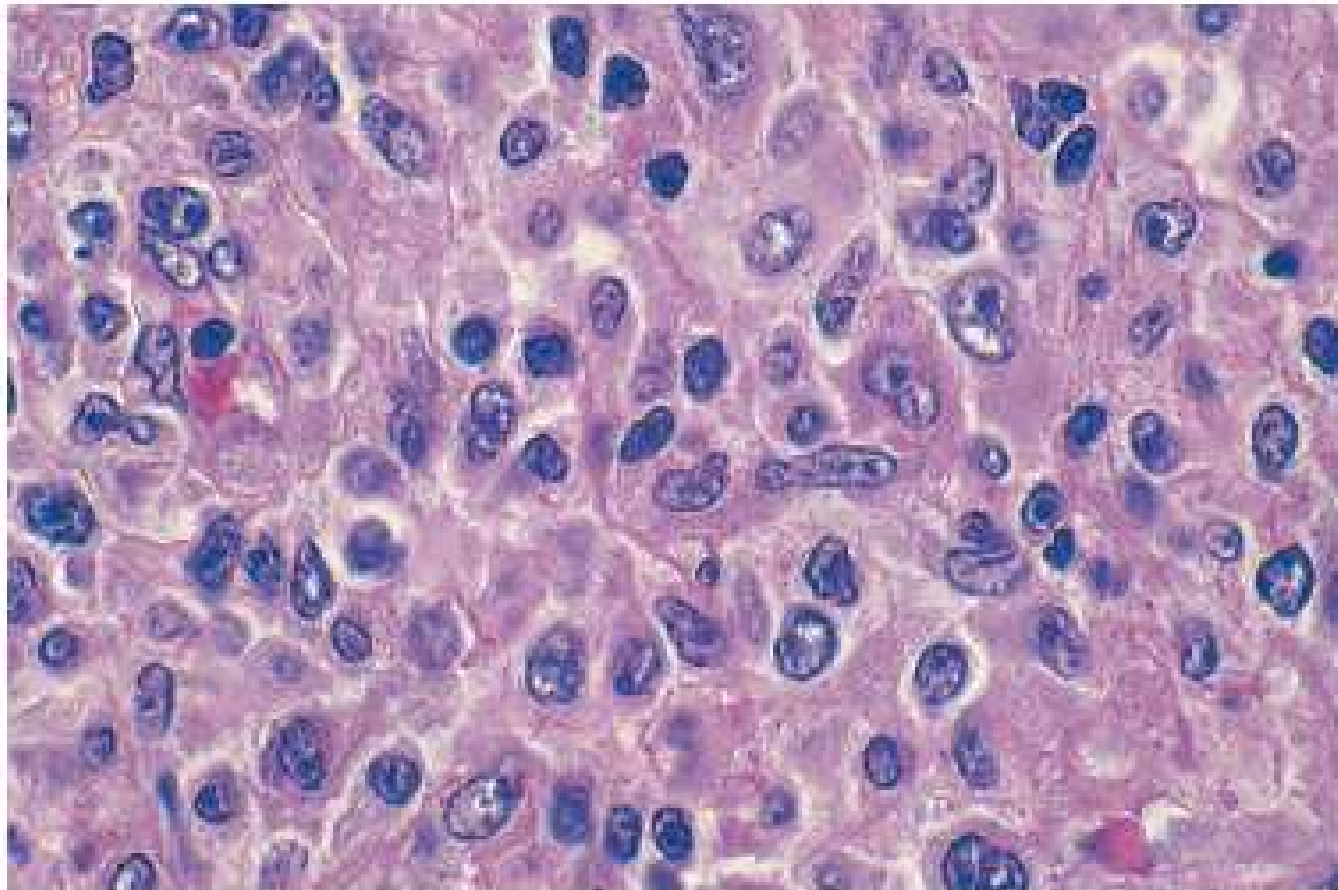
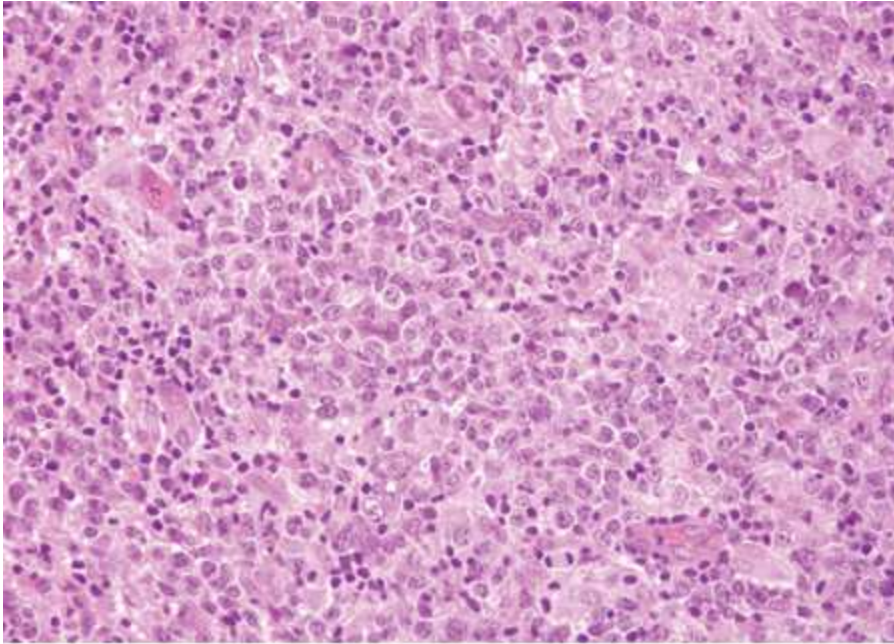


Figure 13-22 Peripheral T-cell lymphoma, unspecified (lymph node). A spectrum of small, intermediate, and large lymphoid cells, many with irregular nuclear contours, is visible.

Peripheral T-cell lymphoma



Neoplastic cells are both small and large.

Fig. 6-10 Accessed 04/27/2010

Source: Kantarjian HM, Wolff RA, Koller CA: *MD Anderson Manual of Medical Oncology*: <http://www.accessmedicine.com>

Copyright © The McGraw-Hill Companies, Inc. All rights reserved.

Enteropathy associated T-cell lymphoma

- Involves GI epithelium. Bone marrow involvement rare.
- Type 1 is associated with celiac sprue.
- CD3+, CD8-, CD103+
- Type II
- CD3+, CD8+, CD56+
- Resection followed by one cycle of CHOP followed by three cycles of ifosfamide/etoposide/epirubicin and intermediate-dose methotrexate followed by autologous stem cell transplantation.

Adult T-cell lymphoma

- HTLV1 associated
- Southern Japan, West Africa, Caribbean
- Generalized lymphadenopathy, hepatosplenomegaly, peripheral blood lymphocytosis, and hypercalcemia.
- Cells with multilobated nuclei (“cloverleaf” or “flower” cells) are frequently observed
- Generally rapidly progressive
- May also be associated with demyelinating disease of the central nervous system and spinal cord

Highly aggressive lymphomas

- Precursor B cell principally found in children.
- Presents as leukemia in 80% and as lymphoma in 20%.
- t(1:19), t(9;22), 11q13, and CD10-, CD34-, CD24- have poor prognosis.
- Aggressive chemotherapy leads to event free survival of 85% and 64% for localized and advanced disease, respectively.

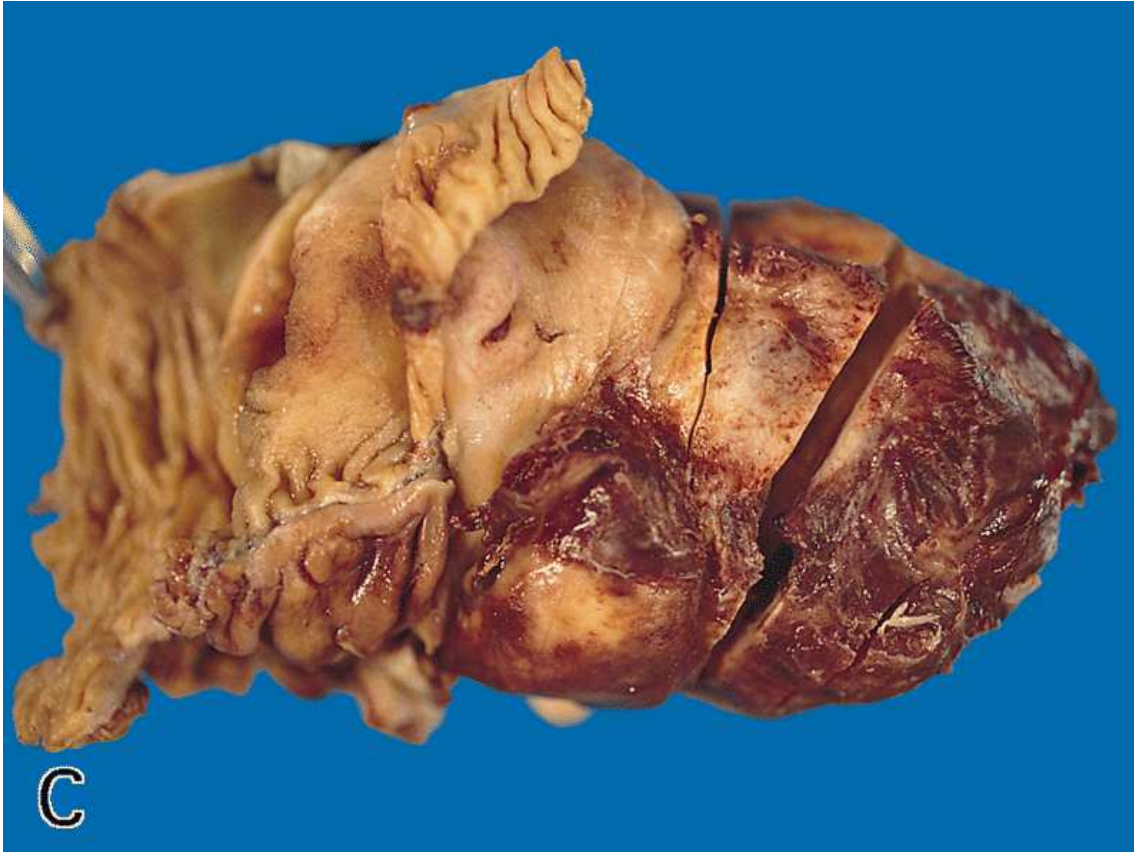Highly aggressive lymphomas

- Diffuse B-cell lymphoma and anaplastic large cell lymphoma are also common in children.
- More aggressive than in adults.
- 3-5% risk of CNS relapse.
- Intrathecal methotrexate prophylaxis.

Highly aggressive lymphomas

- Burkitt's found principally in children
- 40-50% of lymphomas in children.
- Endemic form involves mandible, then kidneys, ovaries, adrenal glands.
- Sporadic form involves mass at the ileocecum and in the peritoneum.
- Mature B-cells of germinal center origin.
- Endemic form demonstrates EBV transcripts.
- Progression free survival 92% at 2 years following therapy

Burkitt's lymphoma

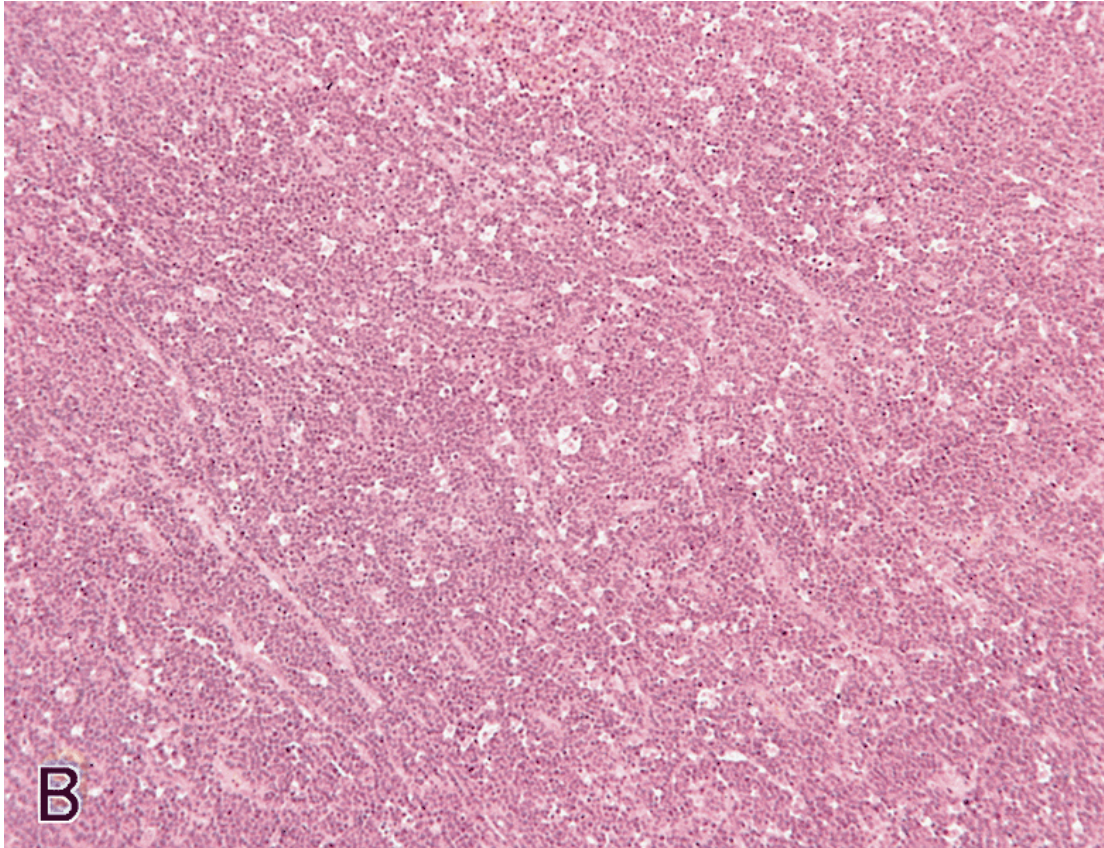


Extensive tumor is pushing into the lumen of the bowel, causing obstructive symptoms, but with a large amount of extramural tumor.

Fig. 8-8C

Riddell, RH, Petras, RE, Williams, GT, Sobin, LH., "Tumors of the intestines." Atlas of Tumor Pathology, Third Series, Fascicle 32. Armed Forces Institute of Pathology, Washington, D.C. 2003.

Burkitt's lymphoma



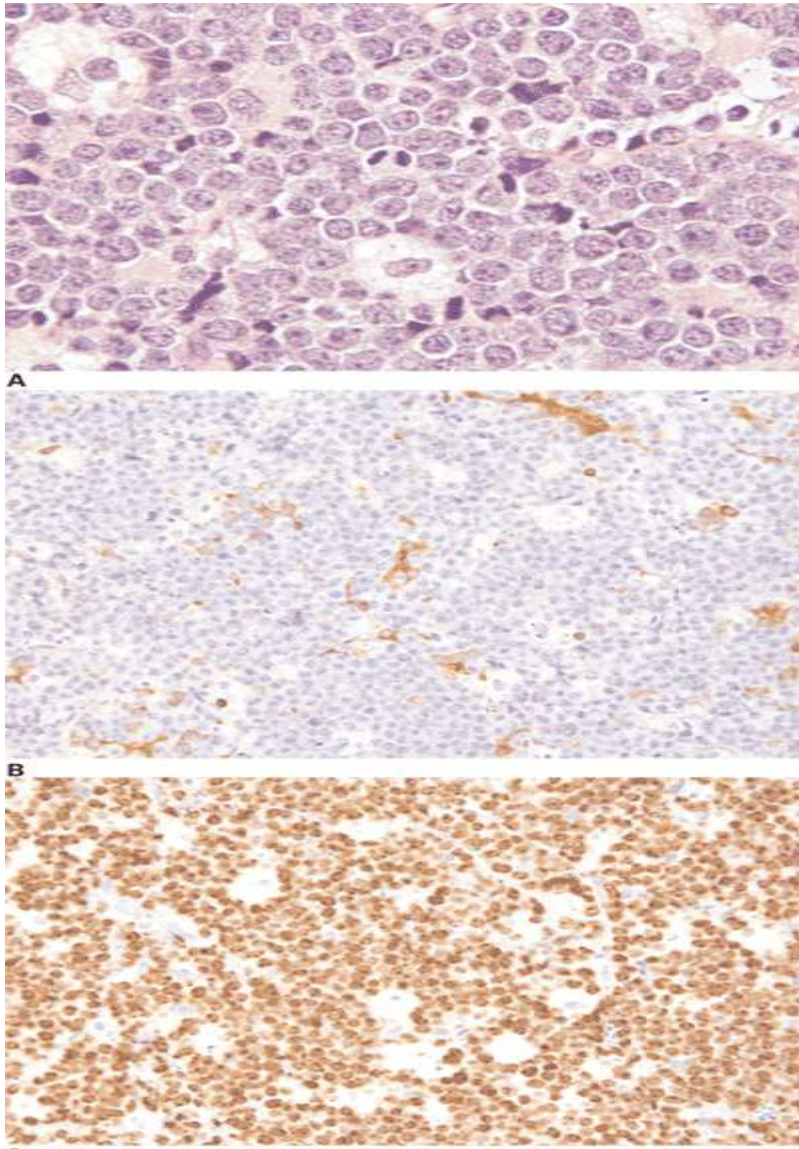
A “starry sky” pattern is evident.

All associated with c-myc abnormalities: t(8;14), involving the IgH locus; t(2;8), involving the Igk locus; or t(8;22), involving the Igλ locus. May also see p53 abnormalities (lead to c-myc overexpression).

Fig. 8-9B

Riddell, RH, Petras, RE, Williams, GT, Sobin, LH., “Tumors of the intestines.” Atlas of Tumor Pathology, Third Series, Fascicle 32. Armed Forces Institute of Pathology, Washington, D.C. 2003.

Burkitt's lymphoma



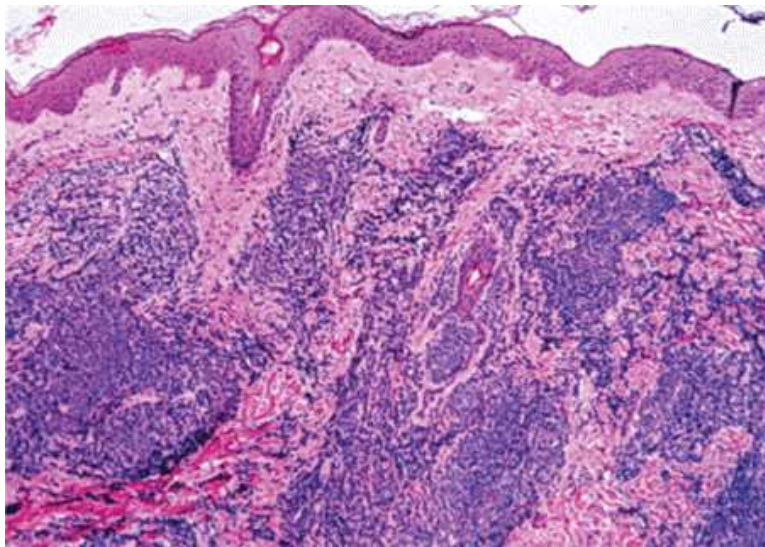
The neoplastic cells are intermediate in size, similar to that of benign histiocyte nuclei, with multiple small nucleoli. A starry-sky pattern is also seen in this field. B,C. The neoplastic cells are negative for BCL-2 (B), and are >99% positive for Ki-67 (C). (A, hematoxylin-eosin, 1000x; B,C, immunohistochemistry, 400x.)

Fig. 6-22 Accessed 04/27/2010

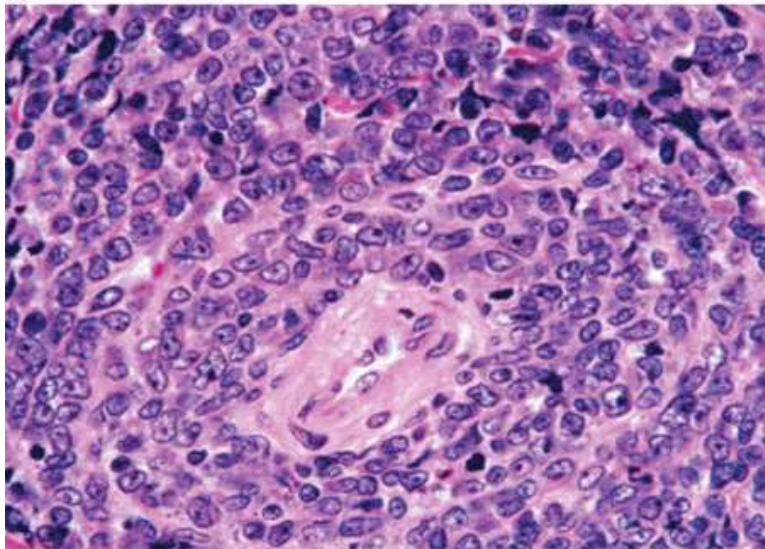
Highly aggressive lymphomas

- Precursor T-cell lymphoma principally found in children (40% of lymphomas, 15% of lymphoblastic leukemias).
- Rapidly enlarging mediastinal mass.
- t(10;14)
- t(11;14).
- 85% and 64% event free survival at 5 years for localized and general disease, respectively, following therapy

Precursor B-cell lymphoblastic lymphoma



A



B

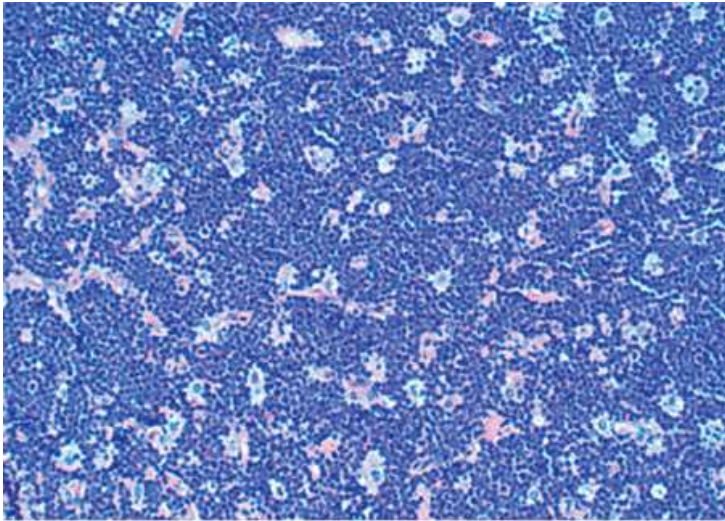
Skin. A. The neoplasm is located predominantly in the dermis. B. At high magnification, the neoplastic cells are small with immature chromatin consistent with lymphoblasts. (A,B, hematoxylin-eosin; A, 100x B, 630x.)

Fig. 6-24 Accessed 04/27/2010

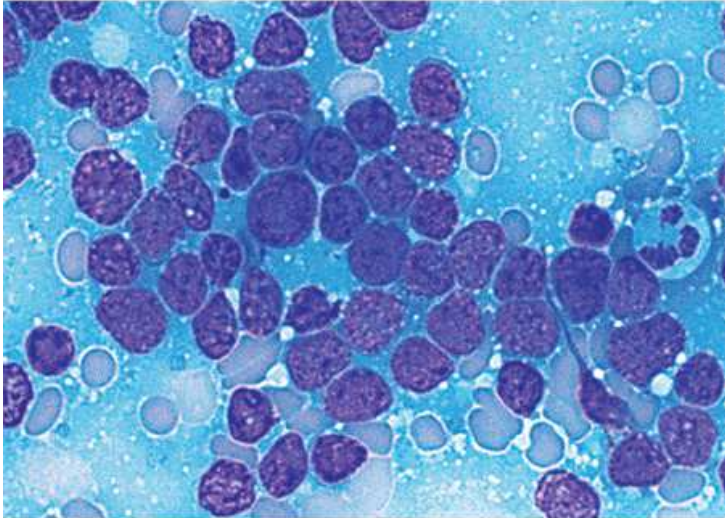
Source: Kantarjian HM, Wolff RA, Koller CA: *MD Anderson Manual of Medical Oncology*: <http://www.accessmedicine.com>

Copyright © The McGraw-Hill Companies, Inc. All rights reserved.

Precursor T-cell lymphoma



A



B

Source: Kantarjian HM, Wolff RA, Koller CA: *MD Anderson Manual of Medical Oncology*: <http://www.accessmedicine.com>
Copyright © The McGraw-Hill Companies, Inc. All rights reserved.

A. At this magnification, the neoplasm has a diffuse pattern and a prominent starry-sky appearance. B. A touch imprint of this specimen shows many lymphoblasts. (A, hematoxylin-eosin, 200x; B, Wright-Giemsa, 1000x.)

Fig. 6-23 Accessed 04/27/2010

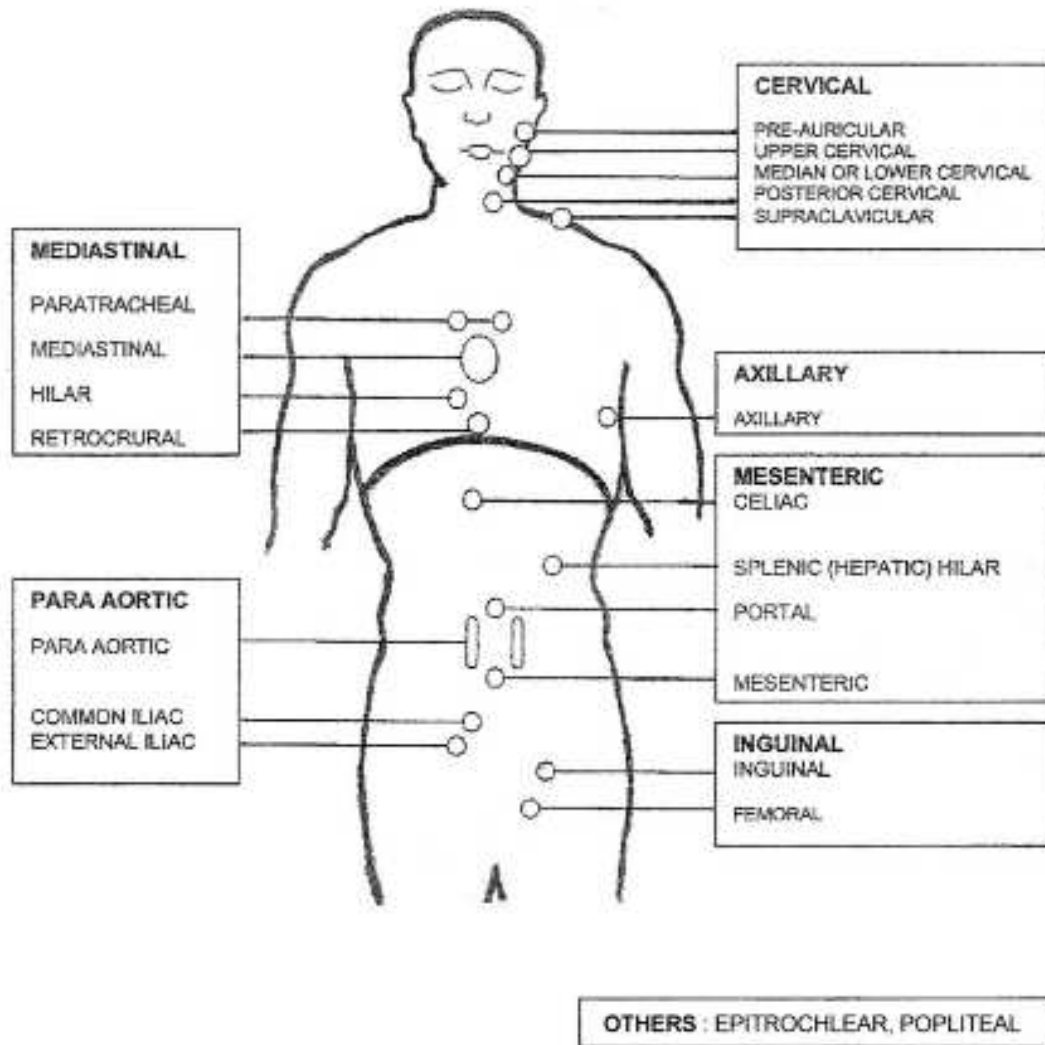
Table 13-7 Differences between Hodgkin and Non-Hodgkin Lymphomas

Hodgkin Lymphoma	Non-Hodgkin Lymphoma
More often localized to a single axial group of nodes (cervical, mediastinal, para-aortic)	More frequent involvement of multiple peripheral nodes
Orderly spread by contiguity	Noncontiguous spread
Mesenteric nodes and Waldeyer ring rarely involved	Waldeyer ring and mesenteric nodes commonly involved
Extranodal presentation rare	Extranodal presentation common

Spleen size

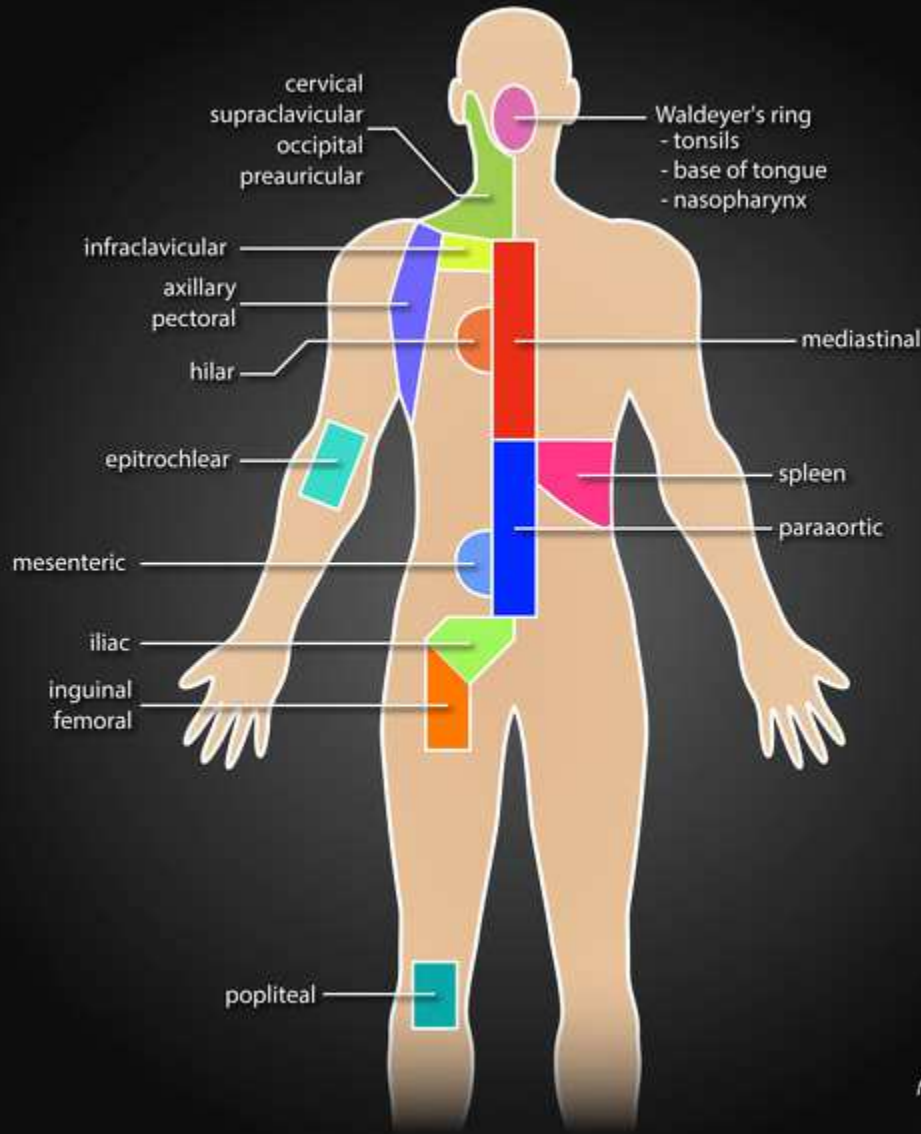
- Percuss for the spleen in the right lateral decubitus position. If dullness is present >8cm above costal margin, the spleen is probably enlarged (positive likelihood ratio, LR+, 3.6; LR- 0.4).
- If the spleen is palpated when the patient is supine, it is probably enlarged (LR+, 8.2; LR-, 0.4).
- If percussion is negative, there is to palpate for the spleen.
- Radiographic examination is used to determine spleen size.

Nodal Sites



Lister TA, Crowther D, Sutcliffe SB, et al. Report of a committee convened to discuss the evaluation and staging of patients with Hodgkin's disease: Cotswolds meeting. J Clin Oncol 1989; 7:1630.

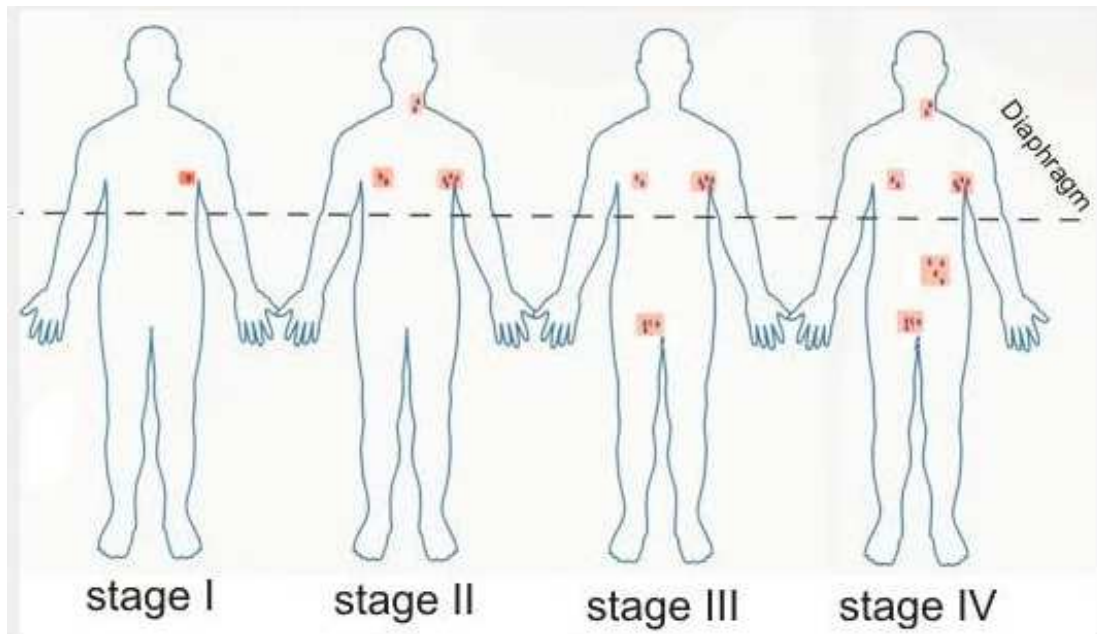
Lymph node regions



<https://radiopaedia.org/articles/lymphoma-staging-1>

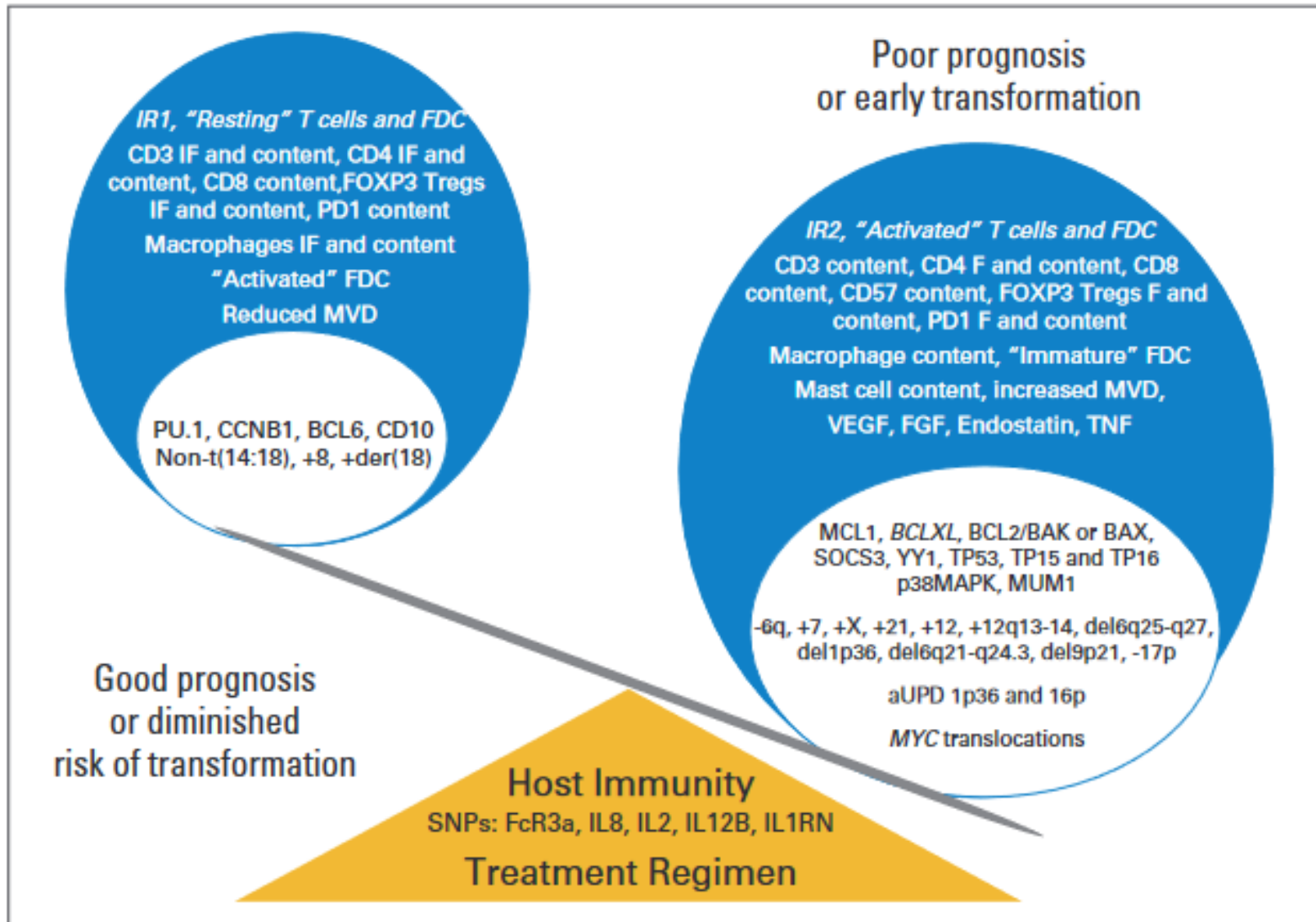
M. Debowski 2014





- Stage I: disease is located in a single region, usually one lymph node and the surrounding area.
- Stage II: disease is located in two separate regions, an affected lymph node or organ and a second affected area. Both affected areas are confined to one side of the diaphragm.
- Stage III: disease involves both sides of the diaphragm, including one organ or area near the lymph nodes or the spleen.
- Stage IV: diffuse or disseminated involvement of one or more extranodal organs, with or without associated lymph node involvement.

<https://www.mdcalc.com/follicular-lymphoma-international-prognostic-index-flipi#evidence>



Relander, T, Johnson, NA, Farinha, P, Connors, JM, Sehn, LH, Gascoyne, RD, "Prognostic factors in follicular lymphoma," JCO (2010) 17:2902-2913
<http://www.pgcmehematology.net/articles/prognostic-factors-follicular-lymphoma.pdf>

Follicular lymphoma international prognostic indices

Table 1. Adverse Factors in the FLIPI and the FLIPI2 Indices	
FLIPI ²⁵	FLIPI2 ³⁰
Age > 60 years	Age > 60 years
Stage III-IV	Bone marrow involvement
Anemia (Hb < 120g/L)	Anemia (Hb < 120 g/L)
Number of involved nodal areas > 4	Nodes > 6 cm
LDH > ULN	β 2-microglobulin > ULN

Abbreviations: FLIPI, Follicular Lymphoma International Prognostic Index; Hb, hemoglobin; LDH, lactate dehydrogenase; ULN, upper level of normal.

FLIP1

Pre-Rituximab validation

Score	Risk Group	10-year Overall Survival
≤1	Low	70%
2	Intermediate	50%
≥3	High	35%

FLIP2

Post-rituximab validation

Score	Risk	Progression Free Survival (5 years)
0	Low	80
1-2	Intermediate	51
3-5	High	19

M7FLIPI

- First prognostic score to incorporate both genetic and clinical factors
- FLIPI risk factors with ECOG performance status and mutations in EZH2, ARID1A, EP300, FOXO1, MEF2B, CREBBP, CARD11 genes
- Most accurate index
- 72%, Low risk: 77% PFS at 5 years
- 28%, High risk: 38% PFS at 5 years

Follicular lymphoma grading

- Grading based on percent of large cells
- Grade I, under 25% or <5 blasts/hpf
- Grade II, 25-50% or 6-15 blasts/hpf
- Grade III, over 50%
- IIIA >15 centroblasts/hpf
- IIIB >15 blasts/hpf with pure sheets of blasts
- Based on highest grade area present
- If two discrete patterns present, lymphoma may be considered composite

Treatment of indolent lymphoma

- Defer therapy until active or progressive disease
- Low tumor burden
- Small cell lymphocytic lymphoma, lymphoplasmacytoid lymphoma, follicular center cell lymphoma of low histologic grade, and extranodal marginal zone lymphoma (MALT)
- CLL is CD5, 23, 43+ with diminished levels of surface immunoglobulin
- 24-30Gy Involved site radiation therapy (ISRT) for curative intent in Stage I-II disease, possibly with rituximab
- Median survival is 10 years.

Treatment of indolent lymphoma

- If asymptomatic III-IV
- Watch and wait
- Treat only if development of B symptoms (other high tumor burden criteria)
- If mild symptoms or relapse, rituximab
- Rituximab maintenance therapy prolongs the remission

Treatment of indolent lymphoma

- any alkylator or CVP have similar efficacy
- Fludarabine 37% CR with 15-18 month median response
- Fludarabine plus cyclophosphamide 90% CR with 75% remaining 3 years
- Relapsers may respond to same regimen [fludarabine, mitoxantrone, prednisone] (47% CR of 21 mo duration median)
- anti-CD20 (Rituximab) has high response (46%), short duration (10mos)
- antibody dependent cell killing

Treatment of indolent lymphoma

- If aggressive follicular lymphoma
- Obinutuzumab/rituximab-CHOP
- Rituximab maintenance
- Early relapses
- Autologous stem cell transplant or rituximab-lenalidomide if <65 years old
- If high tumor burden, Rituximab-CHOP or R-bendamustine

Treatment of indolent lymphoma

- High tumor burden criteria:
- Bulk
 - >6cm node or 3 nodes >3cm in 3 distinct areas
- Splenic enlargement
- Effusions or tumor organ compression
- Elevated LDH or b2microglobulin
- Leukemic phase ($>5 \times 10^9/L$) or cytopenia ($<1 \times 10^9/L$ neutrophils) or platelets $<100K$
- B symptoms

Treatment of indolent lymphoma

- Lenalidomide with rituximab is effective in relapse as well as first-line therapy in mantle cell lymphoma
- Cytopenia is the principal toxicity.
- Enzastaurin, a PKC β inhibitor, is also active in recurrent follicular lymphoma.
- PI₃K inhibitors are active in relapsed or refractory indolent lymphomas.
- Oral therapies with minimal toxicities.

Treatment of indolent lymphoma

- Localized mycosis fungoides can be managed with topical nitrogen mustard or topical retinoid applications.
- Combined modality therapy with subcutaneous interferon- α and oral isotretinoin followed by total-skin electron beam therapy and long term maintenance therapy with topical applications is also employed.
- PUVA therapy (extracorporeal photopheresis) if systemic.
- If CD30 + transformation (up to 55% of cases of mycosis fungoides), median survival 1-3 years.

Treatment of intermediate prognosis lymphoma

- Diffuse small cleaved and mixed, diffuse large, follicular large
- CD 30 +
- bcl-2 expression poor response
- bcl-6 expression associated with extranodal disease (not marrow) and better prognosis
- 20% present with limited disease
- 80% Stage I cured
- ~50% Stage II relapse

Treatment of intermediate prognosis lymphoma

- CHOP
- Radiation therapy is a better choice
- No good relapse regimen
- Bone marrow transplant is an option if sensitive relapse

Treatment of aggressive lymphoma

- Immunoblastic, lymphoplastic, small non-cleaved lymphoma
- Lymphoblastic presents with mediastinal mass
- if >23-30% blasts in marrow is ALL
- 80% cured after CHOP if low risk
- If marrow involvement, elevated LDH, CNS involvement, 5 yr survival is 20%...

Treatment of aggressive lymphoma

- Diffuse small non-cleaved lymphoma is Burkitt's
- Vacuoles, surface immunoglobulin M positive, CD5- with c-myc expression
- Non-Burkitt's lack c-myc
- EBV present in African cases
- 25-40% HIV+
- Generally advanced at presentation, marrow involved in 20%

Treatment of aggressive lymphoma

- 25% Stage IV free from progression at 5 years
- For lesser stages, CR 85% with 50% lasting 5 years
- Bone marrow transplant in sensitive relapse

Treatment of aggressive lymphoma

- Mantle cell lymphoma, centroblastic follicular center cell lymphoma, diffuse large B cell lymphoma, primary mediastinal thymic large cell lymphoma, T-cell lymphomas
- Ibrutinib is the treatment of choice in treatment-naive mantle cell lymphoma.
- Treated with a four (or five) drug regimen:
- Anthracycline, vinblastine, cyclophosphamide, prednisone (and etoposide);
- OR Bendamustine
- This may be followed by autologous stem cell transplantation.

Treatment of aggressive lymphoma

- If no stem cell transplant, chemotherapy is followed by a rituximab, a chimeric monoclonal antibody to CD20.
- However, CD5+ diffuse large cell B cell lymphoma does not benefit from rituximab use
- Activated B cell diffuse B cell lymphoma does not respond well to R-CHOP, but does respond to ibrutinib. Add bortozemib.
- Germinal center B cell diffuse cell lymphoma responds well to R-CHOP
- For CNS lymphoma, add intrathecal or high dose methotrexate to CHOP

Treatment of aggressive lymphoma

- Anthracycline with orchiectomy for testicular lymphoma
- Radio-immunotherapy with ^{90}Yt (chelated to an anti-CD20 mouse monoclonal antibody) following induction therapy has led to prolonged survivals in aggressive lymphoma.
- This is often followed by maintenance therapy with rituximab.
- ^{90}Yt is a pure beta emitter with better therapeutic index than ^{131}I .

Treatment of aggressive lymphoma

- Cyclophosphamide, vincristine, doxorubicin, high dose methotrexate/ifosfamide, etoposide, and high dose cytosine arabinoside as alternative
- Allogeneic bone marrow transplantation in remission may be curative.
- The immune combination of tafasitamab and lenalidomide in the second-line treatment of DLBCL if ineligible for stem cell transplantation.
- Selinexor in relapsed/refractory DLBCL after two or more prior therapies.

Treatment of aggressive lymphoma

- Anti-CD19 CAR-T cells can induce durable remissions in patients with refractory follicular lymphoma or diffuse large B-cell lymphoma.
- Generally ineffective in large cell lymphoma
- Bispecific antibodies (may also use with CAR-T)
- May lead to solid tumor development
- Romidepsin, a histone deacetylase inhibitor, has some activity in T-cell lymphomas (cutaneous or peripheral).

Treatment of aggressive lymphoma

- High-dose methotrexate–based regimens, in combination with Temozolomide, Rituximab induction followed by cytarabine consolidation in those with primary CNS lymphoma
 - 50% induction leads to complete remission
 - 17% resistant
 - 70% complete remission following autologous cell transplant
 - Consolidation makes little difference

Treatment of T-cell lymphoma

- If T-cell lymphoblastic lymphoma, provide CNS prophylaxis
- If precursor T-cell (CD3, CD7, TdT positive)
 - Young men with rapidly enlarging mediastinal mass
 - If NK antigen positive (CD 16, 56) more aggressive
- If post-thymic T-cell (diffuse mixed, mycosis fungoides, angioimmunoblastic, angiocentric, Lennert)
- Respond to CHOP

Treatment of T-cell lymphoma

- Cutaneous (Mycosis fungoides, anaplastic large cell)
- Erythematous patch in MF leading to plaques (10% so present)
- Sezary cells in 25% (marrow not involved)
- Spleen (34%), liver (16%) involved at diagnosis
- Topical mustard use has 30-60% CR
- PUVA effective in limited plaque disease
- Total electron beam effective with low tumor burden
- Single agent chemotherapy as effective as CHOP

Treatment of T-cell lymphoma

- Angio-immunoblastic
- Adenopathy, B symptoms, rash (50%), hyperglobulinemia
- If Stage III-IV, median survival less than 18 months
- Angiocentric (lymphomatoid granulomatosis)
- IFN sensitive
- Asia
- Nose, palate, skin involvement
- Tumor lysis common
- Ara-c/cisplatin effective combination in refractory patients

Tumor lysis syndrome

- Hyperuricemia, hyperphosphatemia, hyperkalemia as a result of rapid lysis of malignant cells.
- Hydrate using Potassium free alkalinizing fluids to maintain urine specific gravity <1.010 .
- Allopurinol essential component of therapy.
- If associated with ureteral obstruction, may require hemodialysis.

Lugano criteria

Modality	Complete Response	Partial Response	Stable Disease	Progressive Disease
CT	<p>Lymph nodes $\leq 1,5$ cm in Ldi</p> <p>Complete disappearance of radiologic evidence of disease</p>	<p>Single lesion: $\downarrow \geq 50\%$ in PPD</p> <p>Multiple lesions: $\downarrow \geq 50\%$ in SPD of up to six lymph nodes or extranodal sites</p>	<p>$\downarrow \leq 50\%$ in SPD of up to six lymph nodes or extranodal sites (no criteria for progressive disease are met)</p>	<p>1) New lymphadenopathy or \uparrow; single node must be abnormal with:</p> <ul style="list-style-type: none"> a) Ldi > 1.5 cm and b) PPD $\geq 50\%$ and c) Ldi or Sdi $\uparrow 0.5$ cm if ≤ 2.0 cm and $\uparrow 1.0$ cm if > 2.0 cm <p>2) \uparrow splenic volume:</p> <ul style="list-style-type: none"> a) with prior splenomegaly: $\uparrow > 50\%$ of its prior \uparrow beyond baseline b) without prior splenomegaly: $\uparrow > 2.0$ cm c) New or recurrent splenomegaly <p>3) New or larger nonmeasured lesions</p> <p>4) Recurrent previously resolved lesions</p> <p>5) New extranodal lesion > 1.0 cm in any axis (new lesions < 1.0 cm in any axis are included if attributable to lymphoma)</p> <p>6) A new node > 1.5 cm in any axis</p>
FDG PET-CT	<p>Scores 1, 2, 3 in nodal or extranodal sites with or without a residual mass</p>	<p>Scores 4 or 5 with \downarrow uptake compared with baseline</p> <p>and</p> <p>residual mass(es)</p>	<p>Scores 4 or 5 with no obvious change in FDG uptake</p>	<p>Scores 4 or 5 in any lesion with \uparrow uptake from baseline</p> <p>and/or</p> <p>New FDG-avid foci</p>

Ldi = longest transverse diameter; Sdi = shortest transverse diameter; PPD = product of perpendicular diameters; SPD = sum of the product of the perpendicular diameters of multiple lesions; \uparrow = increase; \downarrow = decrease

Hodgkin's disease

- <1% of all cancers
- Average age at presentation is 32 years
- 80% of patients have cervical lymph node involvement
- 50% have mediastinal adenopathy.
- The disease proceeds in an orderly fashion from nodes to spleen to liver.

Hodgkin's disease

- WHO recognizes the following types:
- Nodular lymphocyte-predominant
- Classical Hodgkin's lymphoma
 - Nodular sclerosis
 - Lymphocyte-rich classical
 - Mixed cellularity
 - Lymphocyte depleted

Table 13-8 Subtypes of Hodgkin Lymphoma

Subtype	Morphology and Immunophenotype	Typical Clinical Features
Nodular sclerosis	Frequent lacunar cells and occasional diagnostic RS cells; background infiltrate composed of T lymphocytes, eosinophils, macrophages, and plasma cells; fibrous bands dividing cellular areas into nodules. RS cells CD15+, CD30+; usually EBV-	Most common subtype; usually stage I or II disease; frequent mediastinal involvement; equal occurrence in males and females (F = M), most patients young adults
Mixed cellularity	Frequent mononuclear and diagnostic RS cells; background infiltrate rich in T lymphocytes, eosinophils, macrophages, plasma cells; RS cells CD15+, CD30+; 70% EBV+	More than 50% present as stage III or IV disease; M greater than F; biphasic incidence, peaking in young adults and again in adults older than 55
Lymphocyte rich	Frequent mononuclear and diagnostic RS cells; background infiltrate rich in T lymphocytes; RS cells CD15+, CD30+; 40% EBV-	Uncommon; M greater than F; tends to be seen in older adults
Lymphocyte depletion	Reticular variant: Frequent diagnostic RS cells and variants and a paucity of background reactive cells; RS cells CD15+, CD30+; most EBV+	Uncommon; more common in older males, HIV-infected individuals, and in developing countries; often presents with advanced disease
Lymphocyte predominance	Frequent L&H (popcorn cell) variants in a background of follicular dendritic cells and reactive B cells; RS cells CD20+, CD15-, C30-, EB-	Uncommon; young males with cervical or axillary lymphadenopathy; mediastinal

L&H, lymphohistiocytic; RS cell, Reed-Stenberg cell.

Hodgkin's disease

- Nodular lymphocyte predominant
- 4 to 5% of patients
- Men 3:1
- Median age, 40 years
- B symptoms are uncommon
- Usually localized
- Most often involves cervical, axillary, or inguinal lymph nodes
- Mediastinal involvement is rare.
- EBV-.

Hodgkin's disease

- Is a follicular lymphoma
- J chain rearrangement and CD20+
- SGK1, DUSP2 and JUNB mutations
- Clinically indolent.
- 5-6% risk of developing diffuse large B-cell lymphoma
- Splenic involvement, inferior survival
- Stage III/IV or extra-nodal disease is aggressive
- Diffuse T-cell rich pattern associated with higher recurrence

Histopathology

- Usually total replacement of nodal architecture by expansive vague nodules of small lymphocytes
- Sparse, relatively large tumor cells (LP cells)
- Multi-lobulated or round nucleus, thin nuclear membrane, finely granular chromatin and variable small nucleoli (popcorn cells)
- CD4+, PD-1+ T-cells rosette LP cells
- CD20+, CD10-
- Diffuse pattern resembles T cell / histiocyte rich large B cell lymphoma

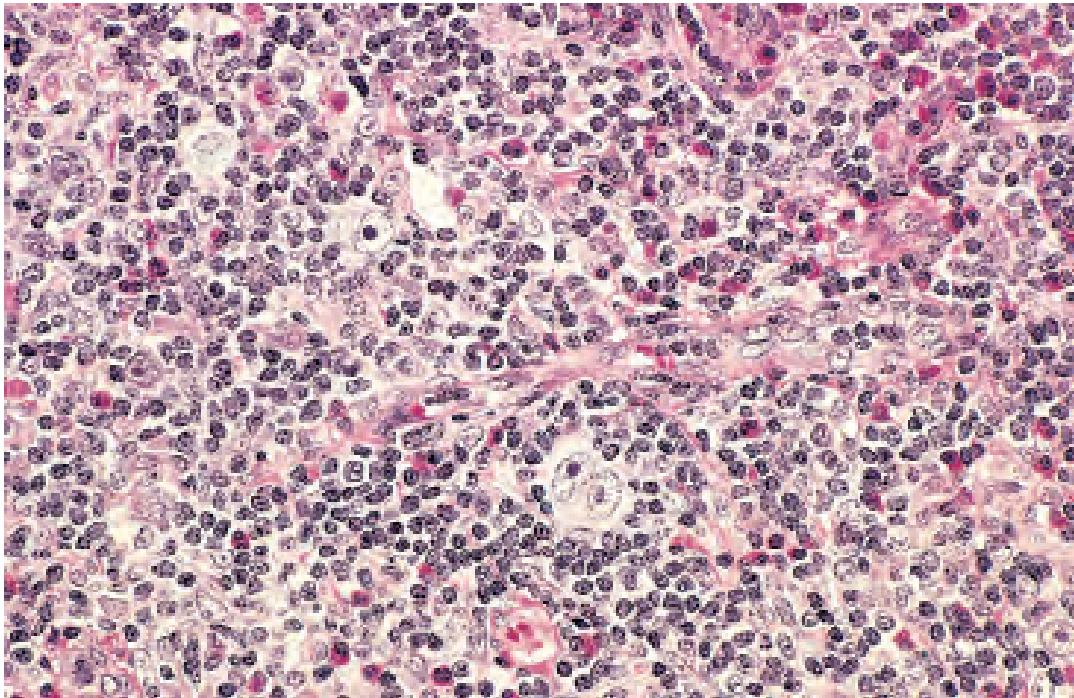
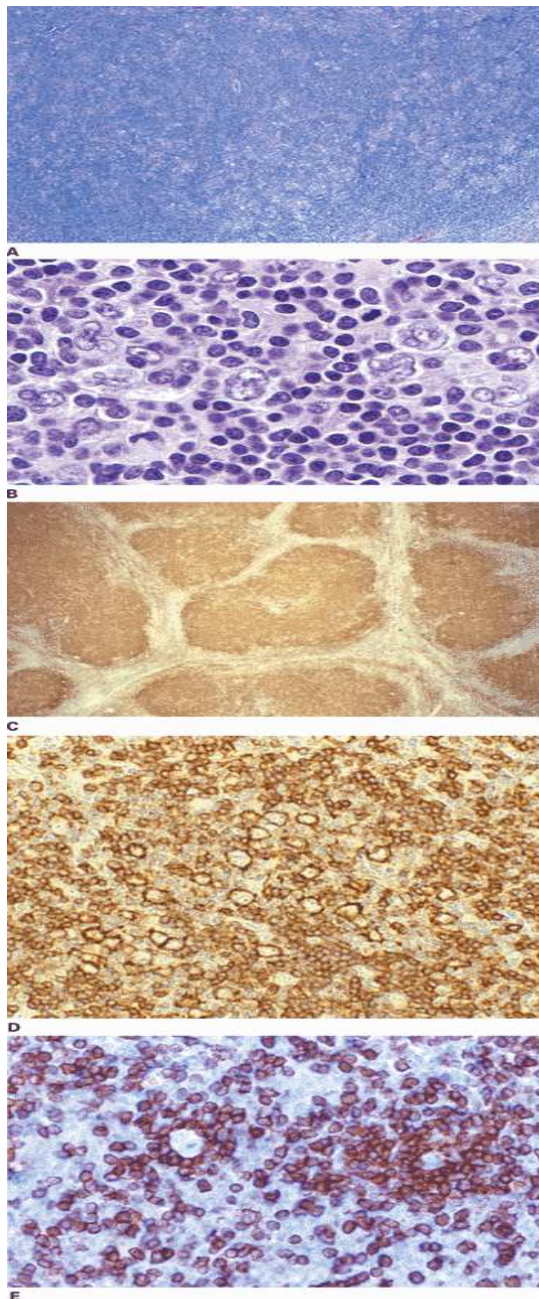


Figure 13-27 Hodgkin lymphoma, lymphocyte predominance type. Numerous mature-looking lymphocytes surround scattered, large, pale-staining lymphohistiocytic variants ("popcorn" cells). (Courtesy Dr. Robert W. McKenna, Department of Pathology, University of Texas Southwestern Medical School, Dallas, Tex.)

Nodular lymphocyte predominant Hodgkin's lymphoma.



A. At low-power magnification, the neoplasm is vaguely nodular. B. At high-power magnification, large L&H cells, resembling popped kernels of corn, are identified in a background of reactive lymphocytes and histocytes. C and D.

Immunohistochemical stain for CD20. C. At low-power magnification, this immunostain highlights the nodular pattern and shows numerous B cells in the nodules. D. At high-power magnification, large L&H cells and small reactive B cells are positive for CD20. E. Immunohistochemical stain for CD3. Scattered small reactive T cells are present and focally surround the L&H cells (so-called rosetting). Fig. 7-1 Accessed 04/27/2010

Hodgkin's disease

- Classical Hodgkin's lymphoma
- 95% of HD
- Peak incidence at 15 and >55 years of age
- 40% have B symptoms
- Four histologic subtypes
- 75% involve cervical nodes
- Nodes may be painful following alcohol consumption
- 60%, mediastinal mass (nodular sclerosis subtype)
- 20%, splenomegaly (mixed cell subtype)
- Rarely relapses.

Histopathology

- Hodgkin Reed-Sternberg (RS) cells are characteristic
- Found in an infiltrate containing a variable mixture of non-neoplastic small lymphocytes, eosinophils, neutrophils, histiocytes, plasma cells, fibroblasts and collagen fibers.
- Hodgkin Reed-Sternberg (RS) cell is large with abundant basophilic / amphophilic cytoplasm
- Binucleate or bilobed nuclei (mirror images)
- Diagnostic Reed-Sternberg cells must have at least 2 nucleoli in 2 separate nuclear lobes

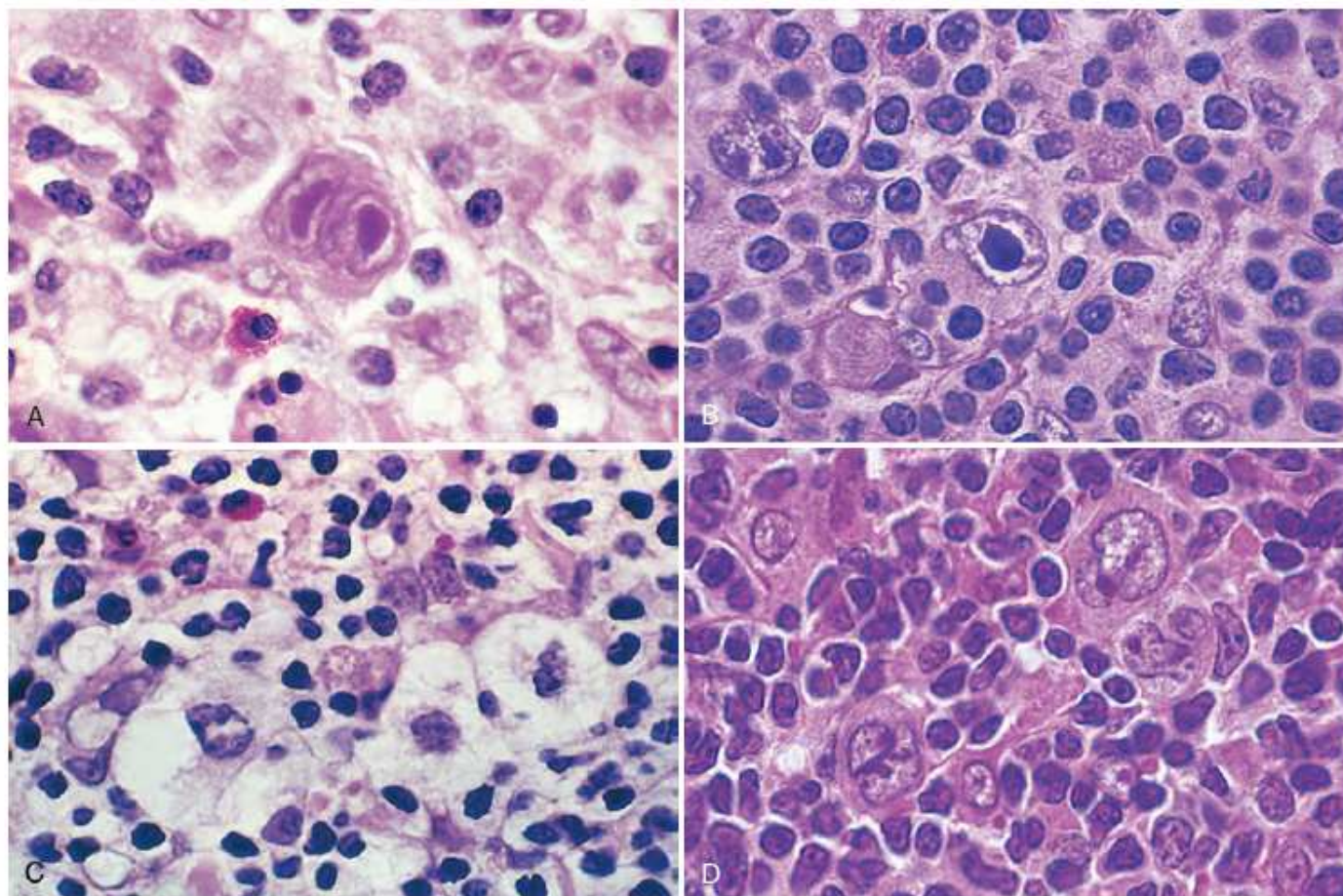


Figure 13-24 Reed-Sternberg cells and variants. **A**, Diagnostic Reed-Sternberg cell, with two nuclear lobes, large inclusion-like nucleoli, and abundant cytoplasm, surrounded by lymphocytes, macrophages, and an eosinophil. **B**, Reed-Sternberg cell, mononuclear variant. **C**, Reed-Sternberg cell, lacunar variant. This variant has a folded or multilobated nucleus and lies within a open space, which is an artifact created by disruption of the cytoplasm during tissue sectioning. **D**, Reed-Sternberg cell, lymphohistiocytic variant. Several such variants with multiply infolded nuclear membranes, small nucleoli, fine chromatin, and abundant pale cytoplasm are present. (A, Courtesy Dr. Robert W. McKenna, Department of Pathology, University of Texas Southwestern Medical School, Dallas, Tex.)

Histopathology

- May have single or multiple multi-lobed nucleoli or large, inclusion-like, owl eyed eosinophilic nucleoli surrounded by clear halo
- Thick, irregular nuclear membrane
- In secondary sites, the presence of CD30+ Hodgkin cells in the background is sufficient to make the diagnosis

Hodgkin's disease

- V(D)J recombination and somatic hypermutation of Ig genes noted in Reed-Sternberg cells
- Post germinal center B-cell origin
- NF- κ B constitutively active
- Negative regulatory of JAK/STAT blocked
- Prognosis related to copy number gains of C-REL gene at 2p16.1
- Reed-Sternberg cells are aneuploid.
- B-cell repertoire genes silenced.
- Surface expression of regulatory receptors retained facilitating interaction with B-cells and CD4+ T-cells.

Hodgkin's disease

- Express chemokines TARC, MDP, IP-10 that enhance T_{H2} response and stimulation of CD40 on Reed-Sternberg cell and upregulation.
- Express chemokine CCL28 that enhances eosinophil response and leads to stimulation of CD30 on Reed-Sternberg cell surface and upregulation. Plasma cells upregulated.
- IL-13 production by Reed-Sternberg cell leads to autogenic stimulation as well as augments T_{H2} response.
- CD30, MHC II, CD80, CD86+

Hodgkin's disease

- C-MET receptor ligates with hepatocyte growth factor produced by dendritic cells
- RAS, PI3K, WNT/ β -catenin pathways activated
- TNF β , basic fibroblast growth factor stimulate CCL11 production and enhance T_{H2} and eosinophil response.
- IL-10, TGF β production suppresses T_{H1} and T_C cells.
- IL-10 mutations associated with GCC haplotype are associated with low failure rates to therapy.

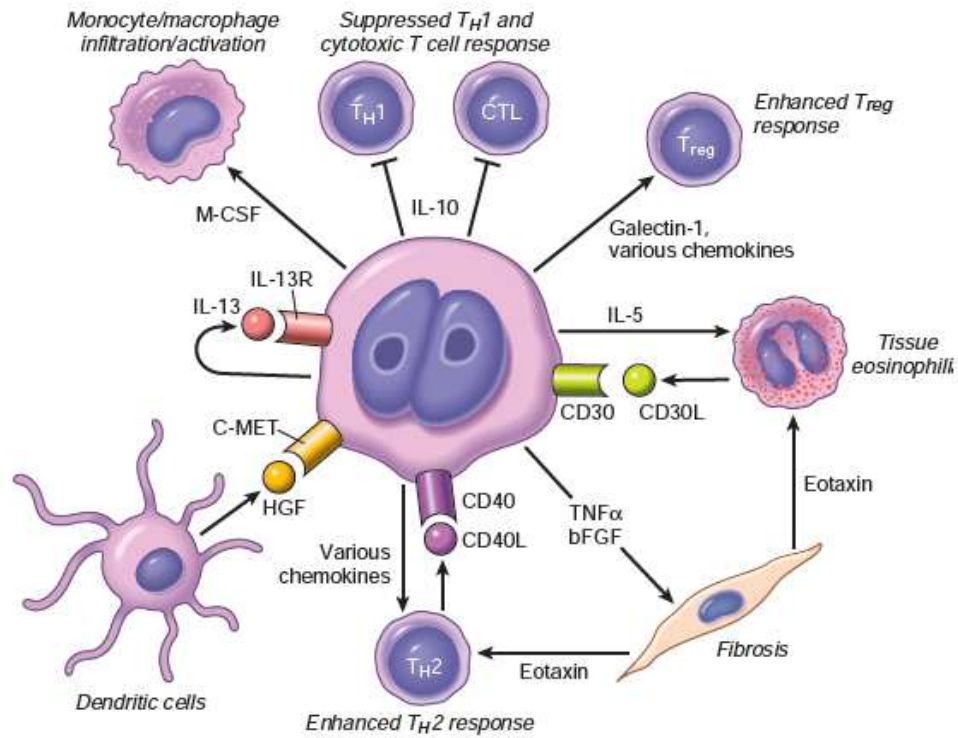
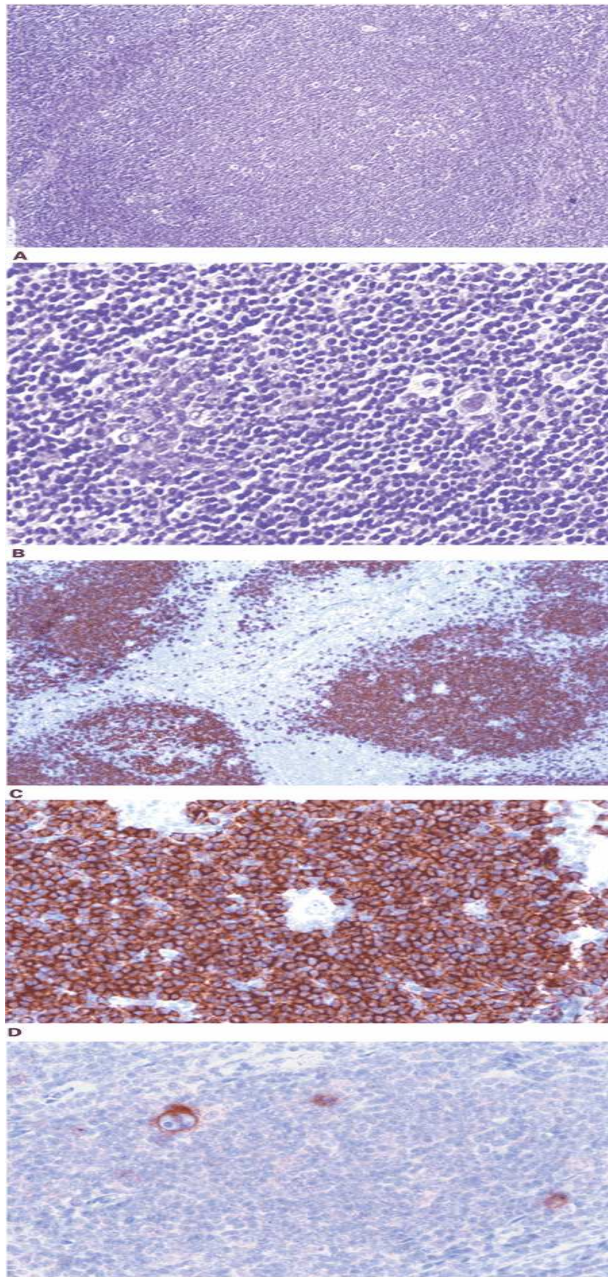


Figure 13-28 Proposed signals mediating "cross-talk" between Reed-Sternberg cells and surrounding normal cells in classical forms of Hodgkin lymphoma. *CD30L*, *CD30* ligand; *bFGF*, basic fibroblast growth factor; *M-CSF*, monocyte colony-stimulating factor; *HGF*, hepatocyte growth factor (binds to the *c-MET* receptor); *TGFβ*, transforming growth factor β; *TNFα*, tumor necrosis factor α; *CTL*, CD8+ cytotoxic T cell; *TH1* and *TH2*, CD4+ T helper cell subsets; *Treg*, regulatory T cell.

Relation to EBV

- 75%, mixed cellularity subtype
- 10-40%, nodular sclerosing subtype
- 100%, HIV related
- Express LMP-1 and EBNA-1
- Do not express EBNA-2

Classical Hodgkin's lymphoma



A. At low-power magnification, the neoplasm has a nodular pattern and is rich in reactive small lymphocytes (resembling nodular lymphocyte predominant Hodgkin's lymphoma). B. At high-power magnification, large neoplastic cells (so-called Hodgkin cells) are identified in the mantle zone of the follicle (note reactive germinal center to left of field). C and D. Immunohistochemical stain for CD20. C. The nodules contain numerous small reactive B-cells. D. The Hodgkin cells are negative for CD20. E. Immunohistochemical stain for CD30. The Hodgkin cells are positive.

Fig. 7-2 Accessed 04/27/2010

Nodular sclerosis Hodgkin's disease

- 65% to 70% of cases of Classical Hodgkin's Disease.
- 15-34 years of age.
- 80%, mediastinal involvement.
- 40%, B symptoms
- 40%, EBV+

Histopathology

- Characterized by the presence of the lacunar cell and collagen bands that divide the lymphoid tissue into circumscribed nodules
- Lacunar cells are a retraction artefact of formalin fixation
- Reed-Sternberg cells are CD15+, CD30+

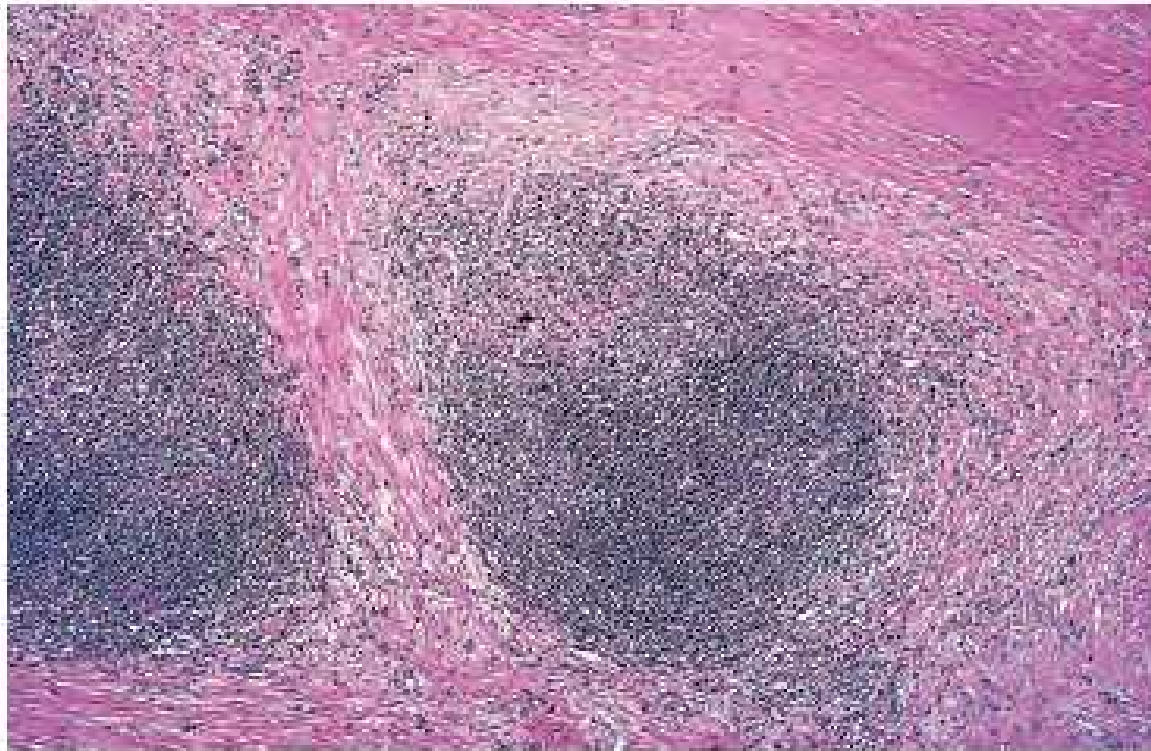
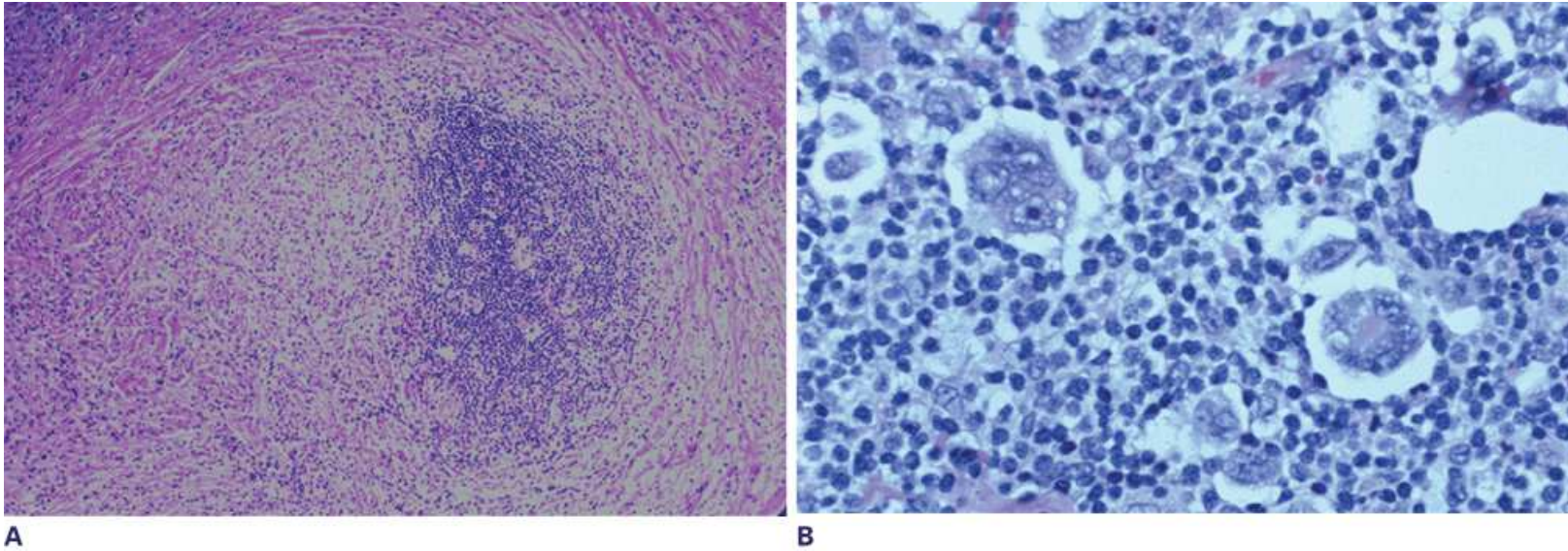


Figure 13-25 Hodgkin lymphoma, nodular sclerosis type. A low-power view shows well-defined bands of pink, acellular collagen that subdivide the tumor into nodules. (Courtesy Dr. Robert W. McKenna, Department of Pathology, University of Texas Southwestern Medical School, Dallas, Tex.)

Nodular sclerosis



Source: Kantarjian HM, Wolff RA, Koller CA: *MD Anderson Manual of Medical Oncology*: <http://www.accessmedicine.com>
Copyright © The McGraw-Hill Companies, Inc. All rights reserved.

Fig. 7-3 Accessed 04/27/2010

A. The neoplasm is nodular and the nodules are surrounded by dense fibrous bands. B. The large neoplastic cells (lacunar cells) lie within lacunar spaces and many are multinucleated in this field. Reactive cells are present in the background.

Mixed cellularity

- 20% to 25% of cases.
- Median age 34 years
- 70% men
- Cervical and supraclavicular nodes
- Frequently involves other peripheral nodes
- 10-30% older men lack mediastinal involvement
- B symptoms common
- EBV+
- Most common subtype in HIV patients

Histopathology

- Diffuse effacement of the lymph node by a heterogeneous cellular infiltrate
- Mononuclear and classic Reed-Sternberg cells abundant.
- May have prominent epithelioid histiocytes and form granulomas
- Reed-Sternberg cells are CD15+, CD30

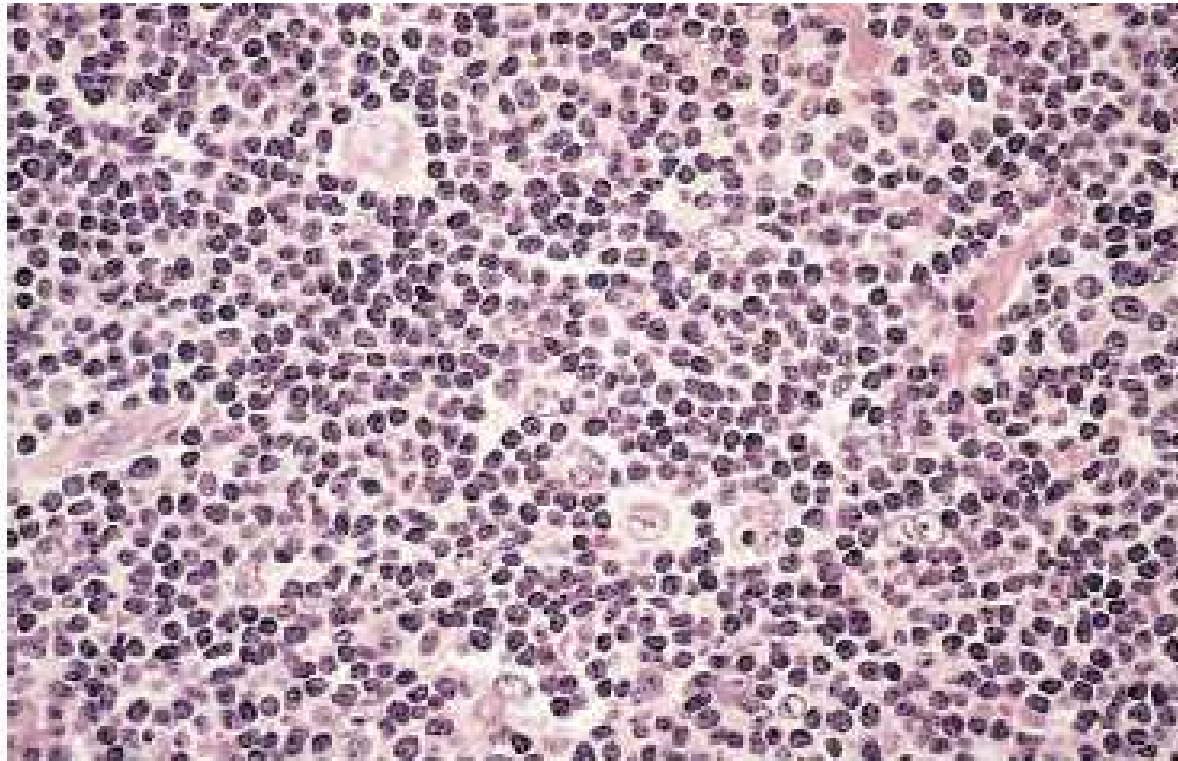
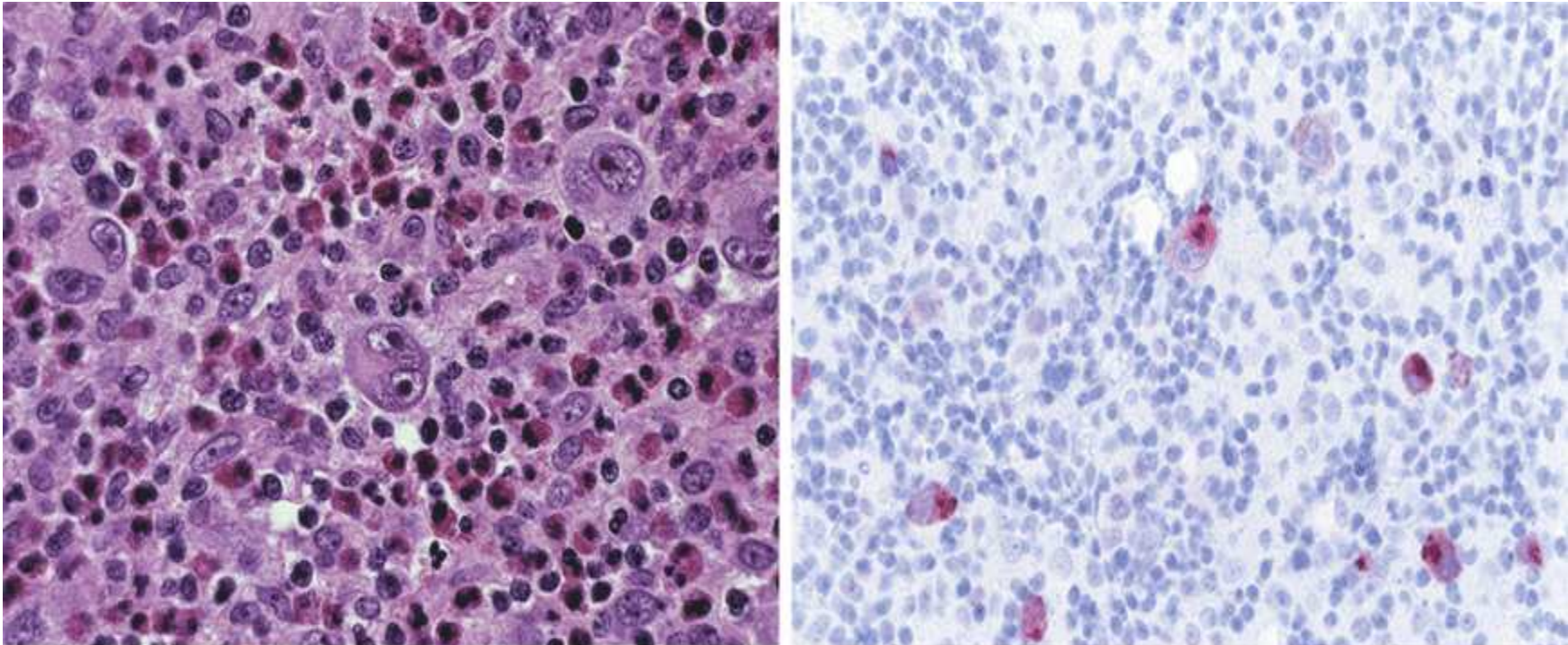


Figure 13-26 Hodgkin lymphoma, mixed-cellularity type. A diagnostic, binucleate Reed-Sternberg cell is surrounded by reactive cells, including eosinophils (bright red cytoplasm), lymphocytes, and histiocytes. (Courtesy Dr. Robert W. McKenna, Department of Pathology, University of Texas Southwestern Medical School, Dallas, Tex.)

Mixed cellularity



A

B

Source: Kantarjian HM, Wolff RA, Koller CA: *MD Anderson Manual of Medical Oncology*; <http://www.accessmedicine.com>

Fig. 7-5 Accessed 04/27/2010

Copyright © The McGraw-Hill Companies, Inc. All rights reserved.

A. Classic Reed-Sternberg cell (center of field) and mononuclear Hodgkin cells can be appreciated in a background of reactive lymphocytes, histiocytes, and eosinophils. B. Immunostain for Epstein-Barr virus latent membrane protein type 1. The neoplastic cells are positive.

Lymphocyte rich

- 5% of classic Hodgkin's lymphoma
- Median age 43 years
- Men 2:1
- Peripheral adenopathy
- B symptoms unusual
- Histopathology:
- Nodular background with scattered Reed-Sternberg cells and small lymphocytes
- Neutrophils and eosinophils absent
- Some Reed-Sternberg cells resemble lacunar cells or LP cells
- CD15, CD30+

Lymphocyte depleted

- 75%, men
- 15-34 years of age
- Often HIV associated
- 90%, subdiaphragmatic disease
- Predilection for retroperitoneal nodes, bone marrow
- 50%, peripheral adenopathy
- Presents with B symptoms
- EBV+.

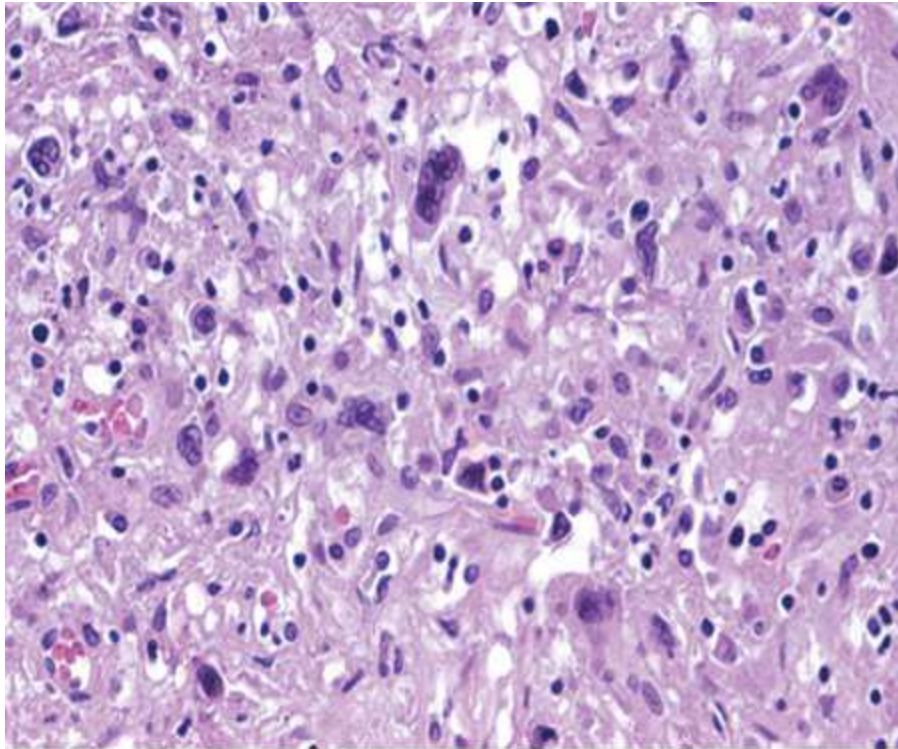
Histopathology

- Reticular variant.
- No disorderly connective tissue
- Numerous bizarre Reed-Sternberg cells in sheets with a paucity of background reactive cells.
- Diffuse fibrosis variant
- Hypocellular PAS+ fibrillar background with scattered diagnostic Reed-Sternberg cells and variants and few reactive cells.
- Reed-Sternberg cells are CD15+, CD30+

Risk factors

- Poor prognostic factors
- Mediastinal mass $>1/3$ chest wall diameter
- B symptoms
- Peripheral nodal masses $>10\text{cm}$
- Abdominal mixed cellularity or nodular sclerosis
poor prognostic factors
- Celiac /splenic involvement better prognosis than
para-aortic/pelvic disease when RT alone used
(celiac 15%/para-aortic 5% patients)

Lymphocyte depleted



**Large neoplastic cells
in the background of
loose, nonpolarized
fibrosis and lymphocyte
depletion.**

Source: Kantarjian HM, Wolff RA, Koller CA: *MD Anderson Manual of Medical Oncology*; <http://www.accessmedicine.com>

Copyright © The McGraw-Hill Companies, Inc. All rights reserved.

Fig. 7-6 Accessed 04/27/2010

Langerhan's histiocytosis

- Unifocal unisystem lesions
- Eosinophilic granuloma
- Generally seen in older children and adults.
- Characterized by expanding, erosive accumulations of Langerhans cells, usually within the medullary cavities of bones.
- Histiocytes are variably admixed with eosinophils, lymphocytes, plasma cells, and neutrophils.
- Pulmonary Langerhan's histiocytosis is seen in adult smokers and often regresses when smoking ceases.

Langerhan's histiocytosis

- Multifocal unisystem Langerhans cell histiocytosis
- Young children
- multiple erosive bony masses that sometimes expand into adjacent soft tissue.
- 50%, diabetes insipidus
- Involvement of the posterior pituitary stalk of the hypothalamus
- Hand-Schuller-Christian
- Calvarial bone defects, diabetes insipidus, and exophthalmos
- Many patients experience spontaneous regression.

Langerhan's histiocytosis

- Multifocal multisystem Langerhans cell histiocytosis
- Letterer-Siwe disease
- Most frequently before 2 years of age
- Occasionally affects adults.
- A dominant clinical feature is the development of cutaneous lesions resembling a seborrheic eruption
- Infiltrates of Langerhans cells over the front and back of the trunk and on the scalp.

Langerhan's histiocytosis

- Most of those affected have concurrent hepatosplenomegaly, lymphadenopathy, pulmonary lesions, and, eventually, destructive osteolytic bone lesions.
- Extensive infiltration of the marrow often leads to anemia, thrombocytopenia, and predisposition to recurrent infections such as otitis media and mastoiditis.
- The course of untreated disease is rapidly fatal.

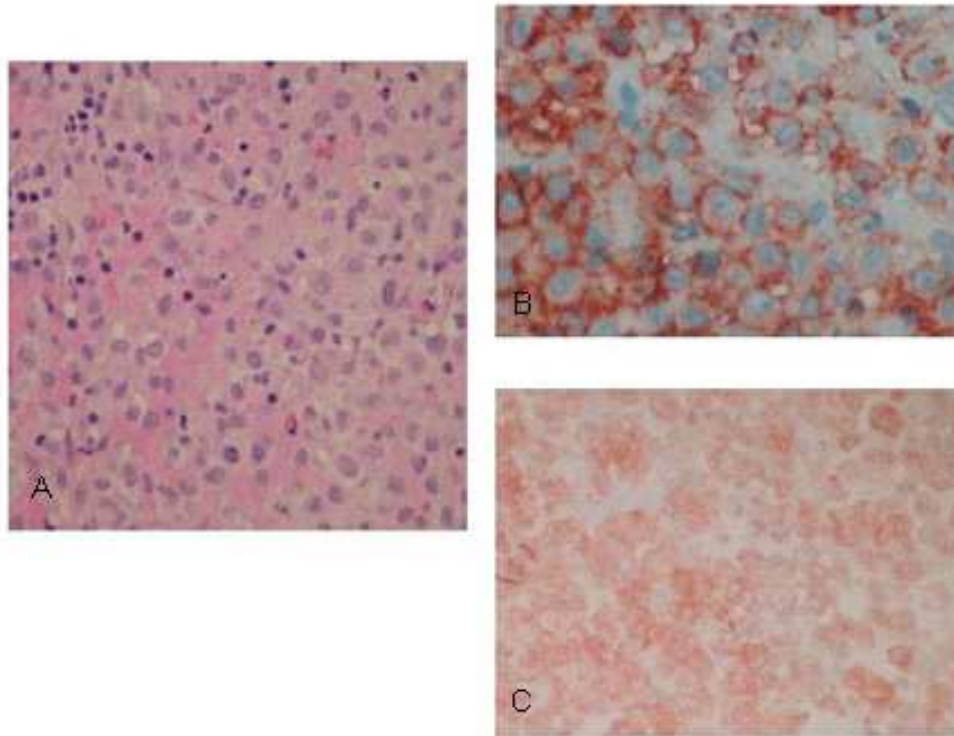
Langerhan's histiocytosis

- The tumor cells are derived from dendritic cells
- Express HLA-DR, S-100, CD207, and CD1a.
- They have abundant, often vacuolated cytoplasm and vesicular nuclei containing linear grooves or folds.
- The presence of Birbeck granules in the cytoplasm is characteristic.
- With electron microscopy, Birbeck granules have a pentalaminar, rodlike, tubular appearance and sometimes a dilated terminal end (tennis-racket appearance).
- S-100, CD207, and CD1a+

Langerhan's histiocytosis

- Whereas normal, skin resident DCs express CCR6, their neoplastic counterparts co-express CCR6 and CCR7, and this allows the abnormal DCs to migrate into tissues that express the relevant chemokines:
 - CCL20 in skin and bone (the ligand for CCR6) and CCL19 and 21 in lymphoid organs (ligands for CCR7).
- BRAF V600E overexpressed.

Langerhan's histiocytosis



A. Characteristic H&E morphologic appearance with sheets of Langerhans histiocytes showing nuclear grooves. A few eosinophils are noted. The Langerhans cells react with the immunohistochemical stain for B. CD1a and C. S100.

Source: Lichtman MA, Shafer MS, Felgar RE, Wang N:
Lichtman's Atlas of Hematology: <http://www.accessmedicine.com>
Copyright © The McGraw-Hill Companies, Inc. All rights reserved.

Fig. X.F.3 Accessed 04/27/2010

Staging

- Lymphangiogram for staging (no CT abdomen if lymphangiogram negative)
- 30-50% Stage I-II have abdominal disease
- Higher stages present if male, older, B symptoms, or mixed cellularity
- Spleen most commonly involved site (number of nodules important)
- CT chest and Gallium scan useful for occult upper torso involvement (abdomen false positive rate is high for Gallium scan)
- Bone Marrow biopsy rarely positive in Stages I-II; results correlate with positive lymphangiogram

Staging

- Laparotomy only if negative abdominal disease
- Nodular scleriosis, women, high neck presentations, and lymphocyte predominance rarely have positive findings on laparotomy in IA disease

Staging

- Pre-therapy staging with PET imaging is essential for the post-treatment assessment of both diffuse large B cell non-Hodgkin's lymphoma and Hodgkin's lymphoma as a negative PET scan after treatment is required for a complete remission and curative outcome.
- A CT scan should also be obtained to assess liver and splenic involvement.
- PET scans are performed 2 months after surgery, 6-8 weeks after chemotherapy, or 8-12 weeks after radiotherapy to avoid equivocal interpretations.

Table 13-9 Clinical Staging of Hodgkin and Non-Hodgkin Lymphomas (Ann Arbor Classification)

Stage	Distribution of Disease
I	Involvement of a single lymph node region (I) or a single extralymphatic organ or site (IE)
II	Involvement of two or more lymph node regions on the same side of the diaphragm alone (II) or localized involvement of an extralymphatic organ or site (IIE)
III	Involvement of lymph node regions on both sides of the diaphragm without (III) or with (IIIE) localized involvement of an extralymphatic organ or site
IV	Diffuse involvement of one or more extralymphatic organs or sites with or without lymphatic involvement
All stages are further divided on the basis of the absence (A) or presence (B) of the following symptoms: unexplained fever, drenching night sweats, and/or unexplained weight loss of greater than 10% of normal body weight.	

Data from Carbone PT, et al: Symposium (Ann Arbor): Staging in Hodgkin's disease. *Cancer Res* 31:1707, 1971.

HD Staging

- Stage I involves a single lymph node region or structure (spleen, thymus, Waldeyer ring) or extralymphatic site.
- Stage II involves two or more lymph node regions on the same side of the diaphragm which may be accompanied by localized contiguous involvement of an extralymphatic site.
- Stage III involves lymph node regions on both sides of the diaphragm which may be accompanied by localized contiguous involvement of an extralymphatic site and/or involvement of the spleen.
- Stage IV is disseminated disease.

HD Staging

- It appears that those patients PET negative after 2-3 cycles of therapy will likely enter into complete remission.
- PET after 2-3 cycles appears to have the same prognostic significance as the PET result after the completion of treatment.
- Absolute lymphocyte count > absolute monocyte count is good prognostic sign.
- PET at autologous stem cell transplant predicts outcome

HD Risk

- Low risk groups are Stages I and II without “B” (constitutional) symptoms. Cure rates are 90% with radiation therapy.
- Bulky disease has cure rates above 80%.
- Stages III and IV are at high risk for recurrence. Cure rates are 60-70% following systemic therapy.
- Nodular lymphocyte predominant Hodgkin’s disease and nodular sclerosing histology in patients <40 years of age, erythrocyte sedimentation rate <50mm/hr, and involving fewer than 3 sites are at low risk for recurrence.

HD Therapeutic strategies

- Localized Hodgkin's lymphoma (CS I-II, supradiaphragmatic) with no systemic symptoms (favorable disease) is treated with radiation therapy
- Extended field to treat unaffected adjacent nodal groups as well
- Mantle/para-aortic 2 fields may be less toxic, but is unacceptable if no previous staging by laparotomy
- Relapse usually at geographic mass
- Favorable features are <4 nodal sites, Nodular Sclerosis or Lymphocyte Predominance histology, Stage IA, no B symptoms, no mediastinal mass, normal ESR, <50 years of age

HD Therapeutic strategies

- In the absence of favorable features
- 2-3 cycles of doxorubicin, bleomycin, vinblastine, and dacarbazine (ABVD) are administered before radiation therapy.
- Para-aortic/abdominal radiotherapy for upper torso presentations
- Radiotherapy alone fails in lungs or pleura
- Localized inguinal disease can be treated safely with Radiotherapy alone...
- Stage IA, high neck, woman, with Nodular Sclerosis or Lymphocyte Predominant histology, treat with involved field Radiotherapy alone

HD Therapeutic strategies

- Stage IIIA
- Total nodal radiotherapy if splenic involvement alone and no mediastinal mass
- 6 cycles of ABVD chemotherapy alone have similar outcome as 2-3 cycles ABVD with radiotherapy
- Do not radiate pelvis if celiac axis/spleen only site and chemotherapy included
- 40-45Gy for peripheral nodes or mediastinal diseases
- 30-35Gy for abdominal disease
- kidneys, liver, lungs tolerate 15Gy

HD Therapeutic strategies

- Stage IIIB/IV
- If also >5 splenic nodules, large mediastinal mass, extensive abdominal disease
- 80-90% Complete Remission with chemotherapy
- 6-8 cycles chemotherapy (2 beyond CR)
- 20-30% relapse
- 85% relapses within 3 years; 95%, 5 years
- Radiotherapy may reduce nodal relapse (20 Gy)
- Cure rates if no B symptoms, 75-80%
- If B symptoms, 55-65%

Radiotherapy strategies

- Mantle therapy (extended field plus mediastinum) if mediastinal disease.
- For subdiaphragmatic disease, an inverted Y field that follows the course of iliac arteries and aorta (and includes spleen) is used.
- A spade field involves aorta and spleen alone.
- In patients with advanced disease, radiation contributes to disease-free survival in those with bulky disease and nodular sclerosis histology.

HD Therapeutic strategies

- Primary progressive disease is treated with a stem cell mobilizing regimen followed by high dose BEAM chemotherapy (BCNU, etoposide, cytarabine arabinoside, melphalan) and stem cell transplant.
- Bulky disease, Stages I-II are treated with ABVD (doxorubicin, bleomycin, vincristine, and dacarbazine) for 6 cycles) if PET negative
- ABVD for 2 cycles followed by BEACOPP (bleomycin, etoposide, doxorubicin, cyclophosphamide, vinblastine, procarbazine, and prednisone) for 4 cycles and radiation therapy if PET positive

HD Therapeutic strategies

- Repeat PET following 2 cycles of ABVD
- If negative, may eliminate need for radiotherapy
- Eliminate bleomycin for succeeding cycles
- Disseminated disease is treated with a four drug regimen: ABVD
- BEACOPP (bleomycin, etoposide, doxorubicin, cyclophosphamide, vinblastine, procarbazine, and prednisone) is equal to ABVD, not cross-resistant, but is more toxic.
- Relapses should be retreated and marrow transplant attempted if relapse <1 year after therapy.

HD Therapeutic strategies

- Stem cell mobilizing therapies, not cross resistant, are (1) dexamethasone, high dose cytarabine arabinoside, and cisplatin; (2) ifosfamide, carboplatin, etoposide; (3) ifosfamide, gemcitabine, vinelbine.
- Gemcitabine, vinblastine, navelbine, and bendamustine active in refractory Hodgkin's lymphoma.
- Brentuximab vendotin (anti-CD30) effective in treatment of relapsed Hodgkin's (CD30+) lymphoma.
- Peripheral neuropathy common.

HD Therapeutic strategies

- Relapse within 1 year of complete remission with ABVD is ominous
- If relapse one year after complete remission, may respond to similar regimen
- But overall cure rate is 45-50%
- as many as 80-90% relapse
- Upper torso nodal relapse may respond to Radiotherapy
- Other chemotherapy combinations less successful

HD Therapeutic strategies

- Bone marrow transplant after BEAM (BCNU, Etoposide, Ara-C, Melphalan) recommended if fewer than 2 prior relapses, low tumor burden, response to salvage chemotherapy
- Mantle radiation and extensive chemotherapy enhance acute toxicity of bone marrow transplant
- Immunotherapy with PD1block favored post-relapse as well as post autologous stem cell transplant in both Hodgkin's disease and in lymphoma

Considerations in pregnancy

- Radiotherapy to upper torso minimal risk in pregnant woman
- Relapses rare in para-aortic/abdomen fields
- Chemotherapy salvage is excellent
- Lesser chemotherapy risk to fetus in second and third trimesters
- Stage with CT chest, abdominal/spleen ultrasonography
- Mantle Radiotherapy in Stage I-IIA disease with abdominal staging more thoroughly following delivery
- Chemotherapy needed in Stage I-IIB, as well as with large mediastinal masses

Late complications of therapy

- Male sterility less common with ABVD but is dose dependent (alkylators, procarbazine generally cause problem)
- Early menopause in 50% women (less risk if <30 years old)
- Leukemia risk in high dose chemotherapy, alkylator use, abdomen/pelvis radiotherapy in those >40 years old, and usually follows myelodysplasia
- Secondary lymphomas usually immunoblastic
- Secondary solid tumors in radiotherapy fields in 15% of treated patients

Late complications of therapy

- Children may experience growth abnormalities
- Hypothyroidism
- Renal dysfunction
- Sepsis risk
- Cardiotoxicity

REVISED IPSS WALDENSTRÖM MACROGLOBULINEMIA SCORING SYSTEM

Criteria for the Diagnosis of Waldenström Macroglobulinemia (only at the time of initial treatment prognostication)

Table 1






	Points
Age <65	0
Age 66–75	1
Age >75	2
B2 microglobulin >4 mg/L	1
LDH >250 IU/L	1
Serum albumin <3.5 g/dL	1















Table 2

Score*	Stage
0	Very Low
1	Low
2	Intermediate
3	High
4–5	Very High

*Sum of total points in table 1

EVIDENCE BLOCKS FOR PRIMARY THERAPY

Preferred Regimens	
Bendamustine/rituximab	
Bortezomib/dexamethasone/ rituximab	
Ibrutinib	
Ibrutinib/rituximab	
Rituximab/cyclophosphamide/ dexamethasone	

Other Recommended Regimens	
Bendamustine	
Bortezomib	
Bortezomib/rituximab	
Bortezomib/dexamethasone	
Carfilzomib/rituximab/ dexamethasone	
Cladribine	
Cladribine/rituximab	
Cyclophosphamide/ doxorubicin/vincristine/ prednisone/rituximab	
Fludarabine	
Fludarabine/rituximab	
Fludarabine/ cyclophosphamide/rituximab	
Ixazomib/rituximab/ dexamethasone	
Rituximab	
Rituximab/cyclophosphamide/ prednisone	

WALDENSTRÖM MACROGLOBULINEMIA/LYMPHOPLASMACYTIC LYMPHOMA THERAPY
(Order of regimens is alphabetical and does not indicate preference)

Therapy for Previously Treated WM/LPL¹

Preferred Regimens

- Bendamustine/rituximab^{2,3,4,10}
- Bortezomib/dexamethasone/rituximab^{3,4,5,6,7,8,10}
- Ibrutinib⁹ ± rituximab^{3,4,10} (category 1)
- Rituximab¹⁰/cyclophosphamide/dexamethasone^{3,4}

Other Recommended Regimens

- Bendamustine⁴
- Bortezomib ± rituximab^{3,4,5,6,7,8,10}
- Bortezomib/dexamethasone^{4,6,7,8}
- Cladribine ± rituximab^{3,4,6,10,12,13}
- Cyclophosphamide/doxorubicin/vincristine/prednisone/
rituximab^{3,4,7,10,14}
- Fludarabine ± rituximab^{3,4,6,10,12,13}
- Fludarabine/cyclophosphamide/rituximab^{2,3,4,6,10,12,13}
- Rituximab^{3,4,10}
- Rituximab¹⁰/cyclophosphamide/prednisone^{3,4}
- Acalabrutinib






Useful In Certain Circumstances













- Everolimus
- Ofatumumab (for rituximab-intolerant individuals)^{3,4,15}



Stem Cell Transplant

- In selected cases stem cell transplantation may be appropriate with either:
 - ▶ Autologous stem cell transplant
 - ▶ Allogeneic stem cell transplant (ablative or nonablative)¹⁶

EVIDENCE BLOCKS FOR PREVIOUSLY TREATED WM/LPL

Preferred Regimens	
Bendamustine/rituximab	
Bortezomib/dexamethasone/rituximab	
Ibrutinib	
Ibrutinib/rituximab	
Rituximab/cyclophosphamide/dexamethasone	

Other Recommended Regimens	
Bendamustine	
Bortezomib	
Bortezomib/rituximab	
Bortezomib/dexamethasone	
Cladribine	
Cladribine/rituximab	
Cyclophosphamide/doxorubicin/vincristine/prednisone/rituximab	
Fludarabine	
Fludarabine/rituximab	
Fludarabine/cyclophosphamide/rituximab	
Rituximab	
Rituximab/cyclophosphamide/prednisone	
Acalabrutinib	*

Useful in Certain Circumstances	
Everolimus	
Ofatumumab (for rituximab-intolerant individuals)	

Venous thromboembolism prophylaxis

- Patient at risk for venous thromboembolism if:
- Stomach cancer (very high risk)
- Lung, lymphoma, GYN, bladder, testicular cancer
- Platelet count $>350,000/\text{fl}$
- Hemoglobin $<10.0 \text{ g/dl}$ (or use of growth factors)
- BMI >35
- Pre-chemotherapy white count $>11,000/\text{fl}$
- Khorana score:
- Each counts one except stomach counts two
- Three or above is high risk

Venous thromboembolism prophylaxis

- LMWH, low dose UFH or fondaparinux prophylaxis for 7-10 days for short hospital stays
- 28 day course if major surgical procedure or advanced malignancy receiving chemotherapy (LMWH preferred)
- If previous episode of venous thromboembolism, prophylaxis continued as long as disease is active